

Dislocation Intermediate Cuneiform with Fracture Medial Cuneiform

Ajay Pal Singh¹, Arun Pal Singh², Vipul Garg³, Jasjot Singh Garcha⁴

What to Learn from this Article?

A rare injury of cuneiforms with a novel treatment method.

Abstract

Introduction: Dislocation of intermediate cuneiform is a rare injury in English language literature. Dislocation of intermediate cuneiform with undisplaced medial cuneiform fracture has been reported only once. We report the first case of dislocation intermediate cuneiform with displaced medial cuneiform fracture.

Case Report: A 43-year-old male was diagnosed of dislocation of intermediate cuneiform with fracture medial cuneiform after a road traffic accident. This was treated by a method of distractor application that is only reported in navicular fracture dislocation. This treatment method avoids open reduction with minimal of complications and good outcome.

Conclusion: Distractor technique was applied for the first time in cuneiform fracture dislocation in this case, and we recommend it to avoid open reduction. The previous reported injuries in this region were mostly treated by open reduction. Due to the rarity of this injury and technique, our case adds to the literature a novel reduction method.

Keywords: Cuneiform, dislocation, distractor, fracture.

Introduction

Stability and highly constrained configuration of the midfoot bones provide it great resilience to bear weight of body [1, 2]. Common injuries are fracture-dislocations of the Chopart and Lisfranc joints [3]. The intermediate cuneiform is wedge shaped bone lying in between the medial and lateral cuneiforms and has strong ligamentous attachments to the first metatarsal. Isolated dislocation of cuneiform is a rare injury [4]. Dorsal dislocation of intermediate cuneiform with undisplaced medial cuneiform fracture is described only once in English language literature [5]. We present in this case report as an unusual midfoot injury pattern with

dorsally dislocated intermediate cuneiform and displaced fracture of medial cuneiform. We also detail the surgical treatment of the patient for reconstruction of articular fragments. To best of our knowledge, this pattern of injury and novel treatment has not been reported till date.

Case Report

A 43-year-old man sustained an injury to his left foot in a road side accident. He sustained this injury following his left foot entrapped in a deep pit followed by sudden twisting strain due to sudden inversion and plantar flexion. The patient presented with severe pain in left foot and was

Access this article online

Website:
www.jocr.co.in

DOI:
2250-0685.618

Author's Photo Gallery



Dr. Ajay Pal Singh



Dr. Arun Pal Singh



Dr. Vipul Garg



Dr. Jasjot Singh Garcha

¹Department of Orthopaedics, Punjab Civil Medical Services, Civil Hospital, Mukerian, Punjab, India, ²Department of Orthopaedics, Kanwar Hospital and Research Centre, Hajipur, Punjab, India, ³Department of Orthopaedics, Singapore General Hospital, Singapore, ⁴Department of Orthopaedics, Garchaz Ortho Trauma Centre, Sangrur, Punjab, India.

Address of Correspondence

Dr. Ajay Pal Singh,
Department of Orthopaedics, Punjab Civil Medical Services, Hoshiarpur, Punjab, India. Phone: +91-987206973.
E-mail: docajaypal@gmail.com

Copyright © 2016 by Journal of Orthopaedic Case Reports

Journal of Orthopaedic Case Reports | pISSN 2250-0685 | eISSN 2321-3817 | Available on www.jocr.co.in | doi: 10.13107/jocr.2250-0685.618

This is an Open Access article distributed under the terms of the Creative Commons Attribution Non-Commercial License (<http://creativecommons.org/licenses/by-nc/3.0>) which permits unrestricted non-commercial use, distribution, and reproduction in any medium, provided the original work is properly cited.

unable to bear weight in his foot. The initial clinical examination of his foot revealed swelling and tenderness on dorsomedial aspect of the right foot. There was no open injury on foot. There was no other associated injury aspect of the dorsum of foot. Plain radiographs including anteroposterior, oblique, and lateral were obtained with showed dorsal dislocation of the intermediate cuneiform bone and a displaced fracture at the medial cuneiform (Fig. 1). The patient was discussed regarding his injury and decision was made for surgical fixation.

Surgical technique

The patient was operated within 6 h of injury. An attempt of closed reduction was attempted after putting patient under general anesthesia but it was not possible to maintain appropriate reduction. Hence, decision was made to put a JESS distractor, to create space between base of metatarsal and navicular with two proximal pins in talus and two dorsal pins in metatarsal head. On applying distraction with JESS assembly fracture of medial cuneiform fell back in place. Further on downward pressure reduction of intermediate cuneiform was achieved but it was very unstable as it came out on slight plantar stress. Therefore, it is further secured provisionally with 2.7 mm K-wire. Single 3.5 mm cortical lag screws were used for intermediate cuneiform with purchase of distal threads in medial cuneiform which was already being stabilized with K-wire. An additional intercuneiform K-wire was also applied (Fig. 2 and 3).

Post-operative radiographs showed good alignment with no distraction of fracture fragment of medial cuneiform with well aligned 2nd medial and middle column of midfoot. A below knee removable splint was given for 3 weeks. The patient was allowed non-weight bearing mobilization from 2nd post-operative day. K-wire and removable splint were taken out at 3rd week. Distractor and K-wire were removed after 6 weeks. The active range of ankle motion started at the same time. The patient was mobilized with weight bearing as tolerated and he started full weight bearing at 8 weeks following surgery. At 3 months of follow-up, plain radiographs revealed fusion of the medial cuneiform and no recurrence of the intermediate cuneiform dislocation. At the final follow-up 18 months after injury, the patient had painless foot with normal range of motion (Fig. 4).

Discussion

The three cuneiforms are wedge shaped and sit in the middle of the medial column of the foot. They are part of the transverse and medial longitudinal arches of the foot. The intermediate cuneiform articulates with one-third of the distal navicular proximally and its respective metatarsal distally [6]. The stability of these bones is achieved by the deep transverse, dorsal, and plantar ligaments.

Isolated dorsal dislocation of intermediate cuneiform is seldom reported in literature. Since first report by Clark, a few reports in association with midfoot fractures are available in English language literature. The dorsal dislocation is more common due to wedge shape and dorsal base position [7].

Most intermediate cuneiform dislocations result from direct injury, but in some cases, indirect injury may cause the dislocation [8]. In one study when the midfoot was under plantar flexion, the intermediate cuneiform was displaced dorsally, but when similar plantar flexion was applied under dorsal midfoot pressure, the intermediate cuneiform was prevented from dislocating dorsally [9]. A plantar flexion force applied to midfoot with a

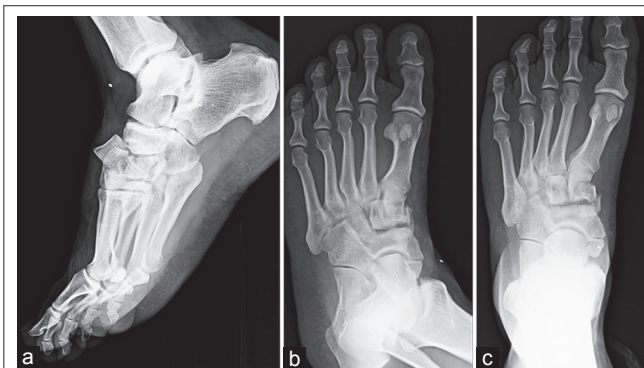


Figure 1: (a-c) Dislocation of intermediate cuneiform with displaced fracture medial cuneiform. The oblique view clearly shows dislocation of intermediate cuneiform.

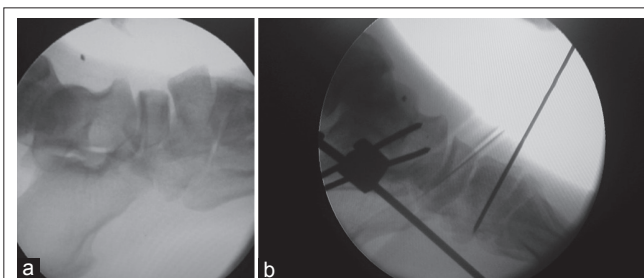


Figure 2: (a and b) Reduction of cuneiform bone after distractor application. A K-wire is used for stabilization.

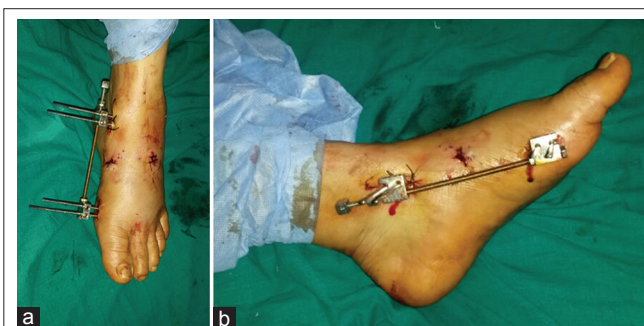

Figure 3: (a and b) Intraoperative pictures of distractor application.

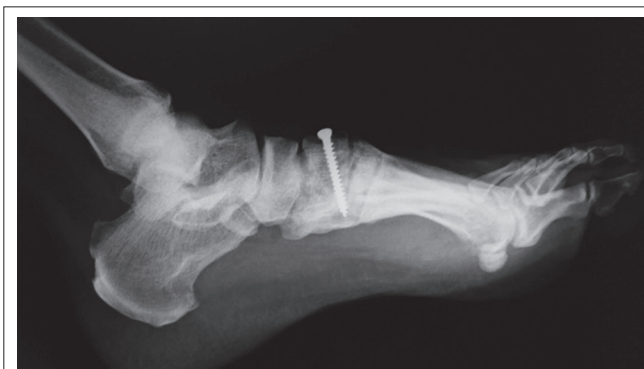

Figure 4: Follow-up radiograph at 1 year.

twist injury is the cause of dorsal dislocation of intermediate cuneiform with displaced fracture of the first cuneiform in this case.

The importance of oblique view is also shown in this case as midtarsal foot anatomy is complicated by overlapping articulations. The overlap makes it difficult to differentiate the dislocation and fractured bones in anteroposterior and lateral views. The oblique view made the diagnosis clear.

Closed reduction has little chance in these injuries, but an attempt was given under anesthesia. Further as dislocation of small tarsal bones devoid them of blood supply a closed reduction was planned. The distractor application is a known technique in tarsometatarsal fracture dislocation [10]. We applied it for the first time in cuneiform fracture dislocation and recommend it to avoid open reduction. The distractor application reduced the fracture and also a slight downward pressure was required to reduce the dislocation of intermediate cuneiform. All previous reports have used open reduction in these dislocations [7, 8, 9]. With distractor application, further fixation requires only mini incisions. The patient has uneventful recovery with no complications.

Regarding resumption of weight bearing in midfoot injuries consensus is almost in favor of delaying weight bearing for at 6 weeks [11]. In our

case, weight bearing is resumed gradually at 6 weeks without any splint and patient progressed to full weight bearing at 3 months following injury without any pain.

Conclusion

Midfoot fracture dislocations are rare injuries to encounter due to stable articulation of joints and ligament. Significant trauma is required for these injuries to take place. Open reduction with distractor application makes it easy to achieve reduction and fix fracture and dislocation. Weight bearing should be slow and delayed as per bony union in these cases to have best outcome.

Clinical Message

A unique pattern of midfoot injury is presented, and the surgical management is detailed for the injury.

References

1. Klaue K. Chopart fractures. *Injury* 2004;35 Suppl 2:SB64-SB70.
2. Doshi D, Prabhu P, Bhattacharjee A. Dorsal dislocation of the intermediate cuneiform with fracture of the Lisfranc joint: A case report. *J Foot Ankle Surg* 2008;47(1):60-62.
3. Nishi H, Takao M, Uchio Y, Yamagami N. Isolated plantar dislocation of the intermediate cuneiform bone. A case report. *J Bone Joint Surg Am* 2004;86-A(8):1772-1777.
4. Early JS. Cuneiform injuries. In: Rockwood CA, Green DP, Heckman JD, Bucholz RW, editors. *Rockwood and Green's Fractures in Adults*. Philadelphia, PA, USA: Lippincott Williams & Wilkins; 2001. p. 2199-2202.
5. Akan B, Yildirim T. Dorsal dislocation of the intermediate cuneiform with a medial cuneiform fracture: A case report and review of the literature. *Case Rep Orthop* 2013;2013:238950.
6. Gray H. *Anatomy of the Human Body*. 37th ed. Edinburgh, Scotland: Churchill Livingstone; 1989.
7. Guler F, Baz AB, Turan A, Kose O, Akalin S. Isolated medial cuneiform fractures: Report of two cases and review of the literature. *Foot Ankle Spec* 2011;4(5):306-309.
8. Aggarwal PK, Singh S, Kumar S. Isolated dorsal dislocation of the intermediate cuneiform: A case report and review of the literature. *Arch Orthop Trauma Surg* 2003;123(5):252-253.
9. Maitra R, DeGnore LT. Isolated dislocation of the middle cuneiform in a farmer: A case report and review of the literature. *Foot Ankle Int* 1997;18(11):735-738.
10. Hardcastle PH, Reschauer R, Kutscha-Lissberg E, Schoffmann W. Injuries to the tarsometatarsal joint. Incidence, classification and treatment. *J Bone Joint Surg Br* 1982;64(3):349-356.
11. Scolaro J, Ahn J, Mehta S. Lisfranc fracture dislocations. *Clin Orthop Relat Res* 2011;469(7):2078-2080.

Conflict of Interest: Nil
Source of Support: None

How to Cite this Article

Singh AP, Singh AP, Garg V, Garcha JS. Dislocation Intermediate Cuneiform with Fracture Medial Cuneiform. *Journal of Orthopaedic Case Reports* 2016 Nov-Dec;6(5):32-34.