Scalloping Sacral Arachnoid Cyst as a Cause of Perianal Pain- A Case Report

Himanshu Ravindra Tyagi[1], Kashmiri Lal Kalra[1], Shankar Acharya[1], Rupinder Pal Singh[1]

What to Learn from this Article?

Presentation and Management of Sacral Arachnoid Cyst.

Abstract

Introduction: Scalloping sacral arachnoid cyst though a rare condition, should be suspected in cases of persistent perianal pain without any obvious urological or anorectal pathology. Such difficult cases justify ordering an M.R.I of spine as plain X-Rays and clinical examination may come out to be inconclusive. X-ray in later stages may show changes corresponding to scalloping of bone due pressure effect of cyst on surrounding tissue. Diagnosis may further be confirmed by doing contrast MRI which differentiates arachnoid cyst from other intradural and extradural pathologies. Though anatomically spinal arachnoid cysts are just an out pouching from the spinal meningeal sac or nerve root sheath they may be extradural or intradural in their location, communicating to main C.S.F column through their pedicle or an ostium leading to continuous enlargement in size.

Case Report: A 32 year old female was admitted under our spine unit with 1.5 year history of chronic pain, swelling and reduced sensation in perianal region. On examination she had tenderness and hypoesthesia over lower sacral region. The pain was continuous, dull aching in nature, not related to activity, localized over lower sacrum and perianal area. The neurological examination of her both lower limbs were unremarkable. Anal tone and anal reflex were normal. No sign of inflammation or tenderness was found over coccyx. Since the X-rays were inconclusive an MRI scan was done which showed a cystic lesion in the sacral area extending from S2 to S4 region with mechanical scalloping effect on the surrounding bone. The lesion had same intensity as C.S.F in both T1 &T2 weighted images. The treatment was done by way of surgical decompression with complete excision of cyst and obliteration of space by a posterior midline approach. Presently the patient is 1 year post operative and no sign of recurrence is there.

Conclusion: Sacral arachnoid cysts should be considered as a differential diagnosis of perianal pain. Large symptomatic sacral cysts should be treated early with complete removal of the cyst including the cyst wall, to reduce the chances of recurrence. Complete decompression of the cyst cavity should be aimed at, but careful dissection of neural element is of highest importance.

Keywords: Perianal pain, sacral arachnoid cyst, arachnoid cyst, spinal cyst.

[1]Dept. of Orthospine, Sir Ganga Ram Hospital, Old Rajinder Nagar, New Delhi, India-110060.

Address of Correspondence
Dr Himanshu Ravindra Tyagi
Dept. of Orthospine, Sir Ganga Ram Hospital, Old Rajinder Nagar, New Delhi, India-110060.
Email:
himanshuravityagi@gmail.com

Author's Photo Gallery


Dr. Himanshu Ravindra Tyagi


Dr. Kashmiri Lal Kalra


Dr. Shankar Acharya


Dr. Rupinder Pal Singh

Journal of Orthopaedic Case Reports | pISSN 2250-0685 | eISSN 2321-3817 | Available on www.jocr.co.in | doi:10.13107/jocr.2250-0685.163

Reviewer's Photo Gallery

Dr. Vivek Mittal

Dr. Rasesh Desai

Introduction

Symptomatic long standing sacral arachnoid cyst may present a confusing picture for the surgeons as sacral arachnoid cyst is rarely symptomatic making the diagnosis difficult [1] [2]. The reported incidence of arachnoid cyst in general population is 1.1% with only less than 20% of these being symptomatic [3]. Arachnoid cyst could be extradural or intradural, with intradural cyst being less common[4]. Perianal pain due to pressure symptoms of a scalloping sacral cyst are difficult to diagnose at early visits as it is a less suspected pathology as compared to other conditions like coccycodynia, gynecological, urological and anorectal fistulas. The diagnosis is further delayed by the inability of plain radiograph to detect the pathology first up. Many a time in absence of a MRI the patient is continued either on painkiller or referred for a psychological help [5]. The differential diagnosis may be a sacral perineural cyst, epidermoid cyst, sacral extradural cyst, occult intrasacral meningocele or anterior sacral meningocele [6]. MRI with or without contrast still remains the old standard test for differentiating arachnoid cyst from other intradural and extradural pathologies [7]. Anatomically spinal arachnoid cysts are out pouching from the spinal meningeal sac or nerve root sheath. According to Nabors MW et. al. arachnoid cysts can be divided into 3 types: Extradural cysts without nerve root fibers (type I), extradural cysts with nerve root fibers including perineurial cysts (type II), and intradural cysts (type III) [8]. Most spinal arachnoid extradural cysts communicate with the subarachnoid space by either a pedicle or an ostium, which allows it to enlarge by acting as a check valve .We here present an interesting case of scalloping sacral arachnoid cyst(type 2 Nabors) as a cause of perianal pain.

Case Report

A 32 year old female was admitted under our spine unit with 1.5 year history of chronic pain, swelling and reduced sensation in perianal region. On examination she had tenderness and hypoesthesia over lower sacral region without any obvious swelling. There was no history of trauma, fever, bladder or bowel dysfunction or any such episode in past. The pain was continuous, dull aching in nature, not related to activity, localized over lower sacrum and perianal area.The neurological examination of her both lower limbs was unremarkable. Anal tone and anal reflex were normal.No sign of inflammation or tenderness was found over coccyx. Plain X-rays of lumbosacral region were not found helpful. Finally an MRI scan was done which showed a cystic lesion in the sacral area extending from S2 to S4 region with size approx 3.5 x 2.4 cm and mechanical scalloping effect on the surrounding bone.The differential diagnosis included Neuroenteric cyst, Epidermoid Cyst, Tarlov cyst, Cystic tumours, Abscess and arachnoid cyst. The lesion appeared hypointense on T1weighted image while hyperintense on T2 weighted image [Fig 1&2] which in turn was of same intensity as that of cerebrospinal fluid column, narrowing down the diagnosis to arachnoid cyst and Tarlov cyst.Since the cyst appeared to be expanded beyond the nerve root (clinical feature of Tarlov cyst) a diagnosis of arachnoid cyst was made radiologically.Rest of the MRI was normal, not indicating any other pathology like disc, yellow ligament hypertrophy or foraminal stenosis which could give rise to similar symptoms. We believe pressure effect of the

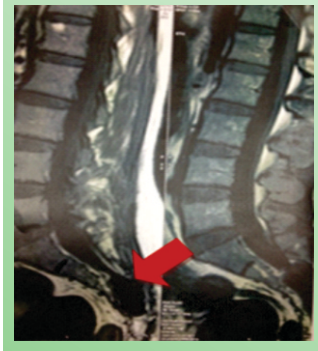

Figure 1: T1 Weighted Sagittal Section Showing Large Cyst in Sacral Region. Cyst Intensity Same as CSF Intensity on T1 Weighted Image (Arrow).

Figure 2: T2 Weighted Sagittal Section Showing Cyst Intensity Same as that of C.S.F with Scalloping Effect on Surrounding Bone (Arrow).

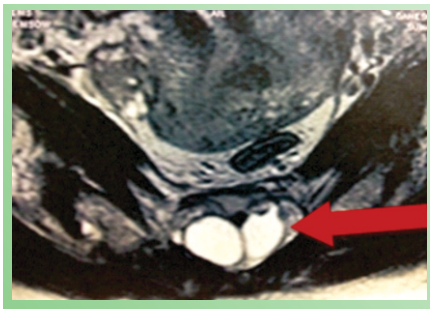

Figure 3: T2 Weighted Axial Section Showing Bilocular Nature of Cyst.

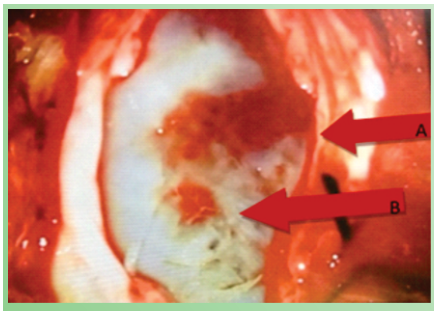

Figure 4: Intraoperative Photograph Showing Large Cyst. Arrow A:Cyst Lining, Arrow B: Ballooned out Cyst Cavity.

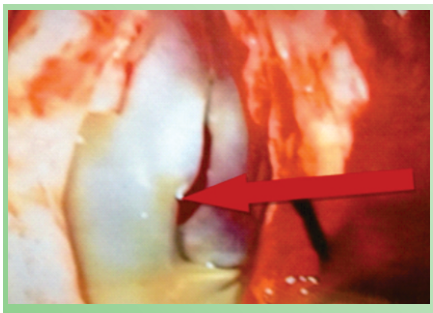

Figure 5: Intraoperative Photograph with Cyst Wall Open Showing Collapsing Nature of Cyst (Small Ostium).

cyst on S3, S4 nerve roots caused the perianal pain due to dermatomal distribution.

SURGERY AND MANAGEMENT: A central decompression was done under GA in prone position by wide S2 to tip of coccyx central laminectomy. On opening up an extradural bilocular cystic [Fig 3] lesion was found ballooning the dura with a small intradural communication channel through right S2 nerve root sleeve. The cyst also had a common wall on left side with exiting S3 nerve root and direct pressure over the lower sacral nerve roots explaining the reduced perianal sensations. Rest of the thecal sac was found normal which was pushed by the cyst to a more proximal level. The cyst wall was opened by midline incision and an arachnoid cyst with a bluish lining was found protruding through the defect [Fig 4] Since it was impossible to remove such a large cyst en bloc, a decision was taken to remove the cyst piecemeal using a microscope. Thus the cyst was opened and clear yellow fluid was evacuated. Immediately the cyst collapsed indicating a sluggish or no communication of the cyst with main CSF column [Fig 5].The cyst lining was removed piecemeal and entire cavity was well curetted for any residual cyst remains. During the entire procedure the nerve roots were protected. The fluid from cyst and cyst lining were sent for histological examination. A CSF leak was encountered during the procedure from around the stalk of cyst which was closed using 6-0 proline. At the end of the procedure, the cavity space was packed with durapatch and was left open for drainage of any future collection. A watertight closure of the incision was performed in layers without a drain to avoid any CSF fistula formation.

HISTOPATHOLOGICAL EXAMINATION: Histopathological examination revealed cyst wall containing fibrocollagenous connective tissue with an inner single-cell arachnoid lining cell with scattered inflammatory infiltrate which confirmed the diagnosis as arachnoid cyst. The fluid sent from the cyst also came out to be normal C.S.F in report.

PATIENT FOLLOWUP: The patient had an uneventful postoperative course in the hospital. Sitting and standing were delayed for few days post operatively to prevent any CSF leak. Patient improved post operatively, and at the time of discharge had no perianal pain. Presently patient is 12 months follow up with no sign of recurrence clinically or radiologically (confirmed on MRI). There are no neurological complaints till date and perianal pain has completely disappeared.

Discussion

Although First described by Spiller in 1903 [9], the first reported incidence was by Nonne in an autopsy finding back in 1898 [10]. Usually the cyst is single but even multiple cysts are reported in literature[10]. Extradural archnoid cyst are most common in thoracic spine (65%) followed by lumbar and lumbo-sacral (13%), thoraco-lumbar (12%), sacral (6.6%), and cervical (3.3%) spine [11].In clinical practice most of the sacral arachnoid cysts are asymptomatic and are discovered incidentally on magnetic resonance imaging [1]. An asymptomatic arachnoid cyst may turn symptomatic over time due to increased pressure effects on nerves and surrounding tissue due to continuous passive fluid transport into the cyst via pulsatile CSF dynamic move due to valve like mechanism at cyst stalk connecting it to subarachnoid space [12]. According to Apoorva kumar et. al sacral arachnoid cyst has an incidence of 6.5% among all arachnoid cysts (thoracic being most common 32.3%)withincidence higher in males and most common in age group between 30 to 45 years [12]. Though many possible mechanism of cyst origin are given in the literature like congenital, traumatic, familial, secondary to non specific arachnoiditis, osmotic gradient transport theory, secretory activity of cyst wall ,we believe valve like mechanism and pressure change theory is most appealing [12].For an asymptomatic cyst, no treatment is required irrespective of the size of the cyst. Symptomatic arachnoid cysts may cause waxing and waning symptoms and may need surgical treatment in the form of complete excision, fenestration, drainage, percutaneous fibrin glue injection or

shunt procedure [13]. Surgeries like aspiration may sound tempting but often fail to give complete relief and increases the chances of re-aspirations, secondary surgery or infection. The preferred treatment of a symptomatic spinal arachnoid cyst is complete surgical removal of the cyst [14]. However in case of an unresectable cyst or dural adhesions, removal of the cyst wall or percutaneous drainage with or withoutshunting the cyst into the peritoneal cavity may relieve symptoms [13]. A newer modality in this field is minimally invasive surgical techniques as described by Neo et al in their work where they successfully management a giant spinal extradural arachnoid cyst by selectively closing the dural defect with clips [7].

Spinal arachnoid cysts can occur at any age and at any spinal level (early teens to upto 80 years of age) [15].The initial clinical presentation may be confusing as symptomatic patients may have low back pain, sacrococcygeal pain, sensory or motor deficit in lower extremities with or without urinary dysfunction mimicking a lumbar disc prolapse [16].In our case, patient presented with chronic perianal pain with hypoesthesia around anal region with MRI not showing any other pathology except the arachnoid cyst, making the diagnosis simple. One simple test to differentiate symptoms from anarachnoid cyst from other pathologies is the increased severity of symptoms during valsalva maneuver if the cyst is symptomatic [17]. We believe that the decision regarding surgery of an arachnoid cyst should be taken after thorough clinical examination and correlation of symptoms with the MRI findings.Usually the postsurgical results are good, resulting in good neurological recover, however chances of recurrence are always there[17].For best results it is advisable to have a thorough radiological evaluation before hand with a logical plan of surgery for proper closure of feeding valve to prevent recurrence. Recurrence rate is much higher after a deroofing procedures like fenestration as compared to complete excision or marsupialization with ostium closure[18].A few more complicated cases have been reported with both intradural arachnoid cysts and syrinx formation were cyst resection resulted in complete resolution of cyst in 3 months[19]. Other situations which may present as a diagnostic dilemma in front of the spine surgeons is arachnoid cyst coexisting with herniated lumbar disc[16]. This situation may be further confused by a positive valsalva maneuver in both the conditions.

Conclusion

Sacral arachnoid cysts should be considered as a differential diagnosis of perianal pain. Large symptomatic sacral cysts should be treated early with complete removal of the cyst including the cyst wall, to reduce the chances of recurrence. Complete decompression of the cyst cavity should be aimed at, but careful dissection of neural element is of highest importance.

Clinical Message

High index of suspicion is required in diagnosing sacral arachnoid cyst as a cause of perianal pain. The cyst may give unusual symptoms ranging from pain, hypoesthesia to neurological involvement. Plain X-ray often may be insufficient in absence of scalloping effect of surrounding bone.A thorough clinical and radiological evaluation is essential before reaching any conclusion.

References

1. *Galzio RJ,Zenobii M, Lucantoni D. Spinal intradural arachnoid cyst. Surg Neurol 1982;17:388–91.*
2. *Takeuchi A, Miyamoto K, Sugiyama S, Saitou M, HosoeH, Shimizu K. Spinal arachnoid cysts associated withsyringomyelia: report of two cases and a review of the literature.J Spinal Disord Tech 2003; 16:207–211.*
3. *Vernooij MW, Ikram MA, Tanghe HL, Vincent AJ, Hofman A, Krestin GP et.al . Incidental findings on brain MRI in the general population. N Engl J Med 2007; 18:1821-8.*
4. *Ertan ERGUN, Alp Özgün BÖRCEK, , Berker CEMIL, Fikret DOGULU.Should We Operate all Extradural Spinal Arachnoid Cysts? Report of a Case. Turkish Neurosurgery 2008, Vol: 18, No: 1, 52-55.*
5. *Erik Van de Kelft, Michel Van Vyve. Chronic perineal pain related to sacral meningeal cyst. Neurosurgery 1991;29:223-6.*
6. *Kato T,Takamura H, Goto S . Sacral perineural cyst, report of a case. Neurological Surgery 1988; 16:893-7.*
7. *Neo M, Koyama T, Sakamoto T, Fujibayashi S, Nakamura T.Detection of a dural defect by cinematic magnetic resonance imaging and its selective closure as a treatment for a spinal extradural arachnoid cyst. Spine 2004; 29:426–430.*
8. *Nabors M.W., Pait T.G., Byrd E.B.,et.al. Updated assessment and current classification of spinal meningeal cyst. J Neurosurg 1988; 68:366-377.*
9. *Takagaki T, Nomura T, Toh E, Watanabe M, Mochida J: Multiple extradural arachnoid cysts at the spinal cord and cauda equina levels in the young. Spinal Cord 2006, 44:59-62.*
10. *Cloward RB: Congenital spinal extradural cysts: case report with review of literature. Ann Surg 1968, 168:851-864.*
11. *Mohammad Ali Bitaraf, Mehdi Zeinalizadeh, Ali Tayebi Meybodi*, Keyvan Tayebi Meybodi , Zohreh Habibi. Multiple extradural spinal arachnoid cysts: a case report and review of the literature. Cases Journal 2009, 2:7531.*
12. *Apoorva kumar, Ridip Sakia, Kulvant Singh,Vivek Sharma. Spinal Arachnoid cyst. Journal of clinical neurosciences 2011;18:1189-92.*
13. *Wang MY, Levi AD, Green B.Intradural spinal arachnoid cysts in adults. Surg Neurol 2003; 60:49–56.*

14. Choi JY, Kim SH, Lee WS, Sung KH.Spinal extradural arachnoid cyst. Acta Neurochir (Wien) 2006;148:579–585.

15. Prevo RL, Hageman G, Bruyn RP, Broere G, van de Stadt J.Extended extradural spinal arachnoid cyst: an unusual cause of progressive spastic paraparesis. Clin Neurol Neurosurg 1999;101:260–3.

16. Muthukumar N.Sacral extradural arachnoid cyst. A rare cause of low back and perineal pain. Eur Spine J 2002;11:162–6.

17. F. Jensen, V. Knudsen,S. Troelsen.Recurrent intraspinal arachnoid cyst treated with a shunt procedure: Acta neurochirurgica1977; 39:127-9.

18. Oertel JM,Wagner W,Mondorf Y,Baldauf J. Endoscopic treatment of arachnoid cystd: a detailed account of surgical techniques and results.Neurosurgery2010;67(3):824-36.

19. Holly LT, Batzdorf U. Syringomyelia associated with intradural arachnoid cysts. J Neurosurg Spine 2006;5:111–116.

Conflict of Interest: Nil
Source of Support: None

How to Cite this Article:
Tyagi HR, Kalra KL, Acharya S, Singh RP. Scalloping Sacral Arachnoid Cyst as a Cause of Perianal Pain- A Case Report. Journal of Orthopaedic Case Reports 2014 April-June;4(2): 28-32