Case Report
Journal of Orthopaedic Case Reports 2014 April-June;4(2): Page 60-63

Fracture of the Anterior Locking Flange of a Total Knee Arthroplasty Polyethylene Liner Presenting with Pain following Knee Replacement

Richard Jeavons[1], Daniel Dowen[2], Paul Rushton[3], Daniel Ryan[1], Peter Gill[2]

What to Learn from this Article?

Unusual Complication of TKR with its Management.

Abstract

Introduction: Fracture of the modern polyethylene insert of a total knee arthroplasty is rare. We describe the first case of a fractured anterior locking flange of the commonly used Depuy Press-fit Condylar (PFC) Sigma prosthesis.

Case Report: The 80 year old Caucasian gentleman presented 8 years following previously uncomplicated and successful primary total knee replacement with pain, swelling and symptoms of instability of the knee. He was able to sublux his knee posteriorly using his hamstrings. Dissociation of the liner was evident on radiographs. He underwent revision of the polyethylene liner. It was evident during the revision that the anterior locking flange of the polyethylene liner had fractured allowing it to dissociate from the tibial tray. At 12 months following this revision he continues to do well and has similar range of movement and function to prior to the episode. This cause of the failure is not clear.

Conclusion: Surgeons should be aware of this rare complication when assessing a painful or unstable total knee replacement.

Keywords: Arthroplasty; revision; implant failure.

Author's Photo Gallery


Dr. Richard Jeavons


Dr. Daniel Dowen


Dr. Peter Gill


Dr. Paul Rushton


Dr. Daniel Ryan

Reviewer's Photo Gallery


Dr. Ashwin Kasturi


Dr. Santosh Banshelkikar

[1]Orthopaedic Registrar, Darlington Memorial Hospital, Darlington, United Kingdom.
[2]Orthopaedic Registrar, Sunderland Royal Hospital, Sunderland, United Kingdom.
[3]Orthopaedic Registrar, Royal Victoria Infirmary, Newcastle upon Tyne, United Kingdom.

Address of Correspondence
Dr. Richard Jeavons, 20 Fairway Court, Fletcher Road, Gateshead, Tyne and Wear, NE8 2AY, England. E-mail: richardjeavons@yahoo.co.uk

Journal of Orthopaedic Case Reports | pISSN 2250-0685 | eISSN 2321-3817 | Available on www.jocr.co.in | doi:10.13107/jocr.2250-0685.170

Introduction

Fracture of the modern polyethylene insert of a total knee arthroplasty (TKA) and rare, the cause of less than 1% of revisions [1]. We describe what we believe the first report of a fractured anterior locking flange and associated dissociation of the polyethylene insert in a Depuy Press-fit Condylar (PFC) Sigma TKA (DePuy, Leeds, UK). This was a problem with the original PFC modular TKA, which was first introduced in 1984 and subsequently revised to the current PFC Sigma in 1996, addressing amongst other issues this previous design fault [2]. This case serves to educate surgeons and the manufacturer that, albeit rare, this complication can still occur with this commonly used TKA. This diagnosis should be considered in patients presenting with a painful or unstable TKA which was previously doing well.

Case Report

Clinical history and examination:

An 80 year old Caucasian male presented to an arthroplasty review clinic 8 and a half years following the insertion of a primary DePuy PFC Sigma Posterior Stabilised (PS) TKA (size 3 tibial tray, size 3 femoral component and 15mm tibial stabilised insert).

The initial procedure had been uneventful and the post operative x-rays were deemed satisfactory. He had complained of some anterior knee pain, 1-2 years post operatively. This was attributed to sight overhang of the patella laterally. The patient declined any further surgery at that time as he was extremely mobile, managing long walks and cycling. His range of movement at that time was from 0-120 degrees flexion. As a precaution, his inflammatory markers were checked and found to be within normal limits.

At 5 years follow up, he had no complaints and was pain free. He was given a review appointment for a further 5 years.

He represented early, however, at 8 and a half years post operatively, complaining about pain in the knee, with episodes of swelling and instability. Interestingly, he was able to sublux his knee posteriorly, using his hamstrings [Fig 1]

Investigations:

Radiographs showed an inverse shadow of the polyethylene liner protruding anteriorly over the tibial tray. There was no sign of loosening of the tibial tray or femoral component [Fig 2]. This suggested anterior polyethylene subluxation: this subtle sign has been described as indicative of failure of the locking mechanism in posterior-stabilized prostheses [3].

Treatment:

He was operated on one month later. On making the arthrotomy of the knee, it was apparent that the polyethylene liner had dissociated from the tibial tray and was protruding anteriorly [Fig 3]. On removing the tibial insert it was found that the anterior locking flange on the under surface had fractured from the liner, allowing it to dissociate from the tibial tray. There was a line of wear along the base of the anterior aspect of the stabilising peg, as well as the posterior aspect of the tip of the peg [Fig 4]. This was attributed to abnormal articulation with the femoral component in the dissociated position. The femoral and tibial components were securely attached and undamaged. They were, therefore, left in-situ and the polyethylene liner was replaced with a new size 3, 15mm stabilised insert.

Outcome:

The patient continued to do well at over 12 months postop. He had a stable knee with similar range of movement to that prior to this episode.

Discussion

In 2010 81,979 primary total condylar knee prostheses were inserted in the UK, of those, 36% were the PFC Sigma, with a revision rate for this prosthesis of 1.7% at 5 years. Of the 5082 knee arthroplasty revisions undertaken in the UK in 2010, 14% were for wear of the polyethylene liner, and less than 1% for component fracture, however there are no further details

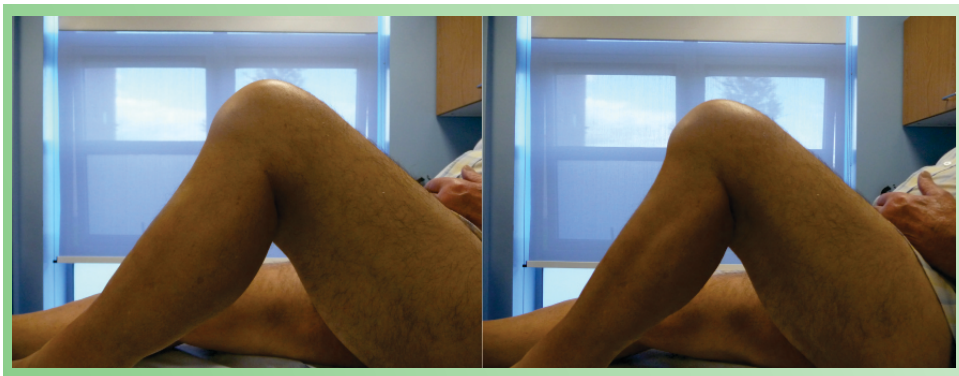

Figure 1: Posterior Subluxation of Knee.

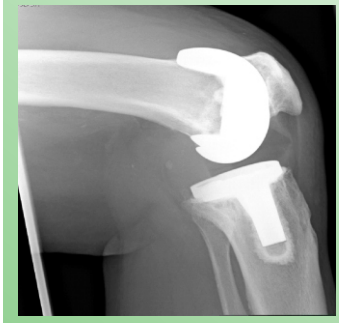

Figure 2: Lateral X-ray of PFC Prosthesis, Showing Anterior Polyethylene Subluxation.

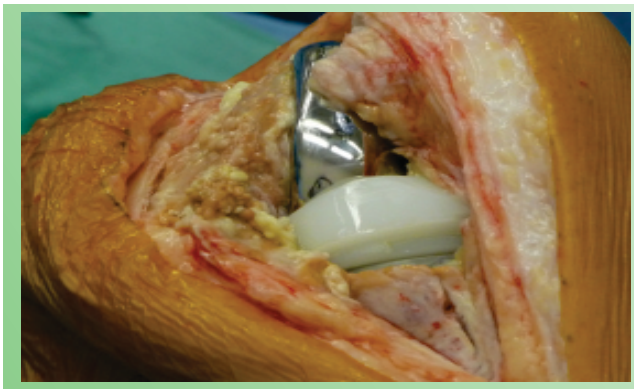

Figure 3: Polyethylene Liner Protruding Anteriorly from Tibial Tray.

Figure 4: Line of Wear along the Base of the Anterior Aspect of the Stabilising Peg and Posterior Aspect of the Tip of the Peg.

on which component was fractured [1]. The mid-term results for this knee system have been very good, with excellent outcome scores and survivorship [4-8]. In a multicentre study of 1970 PFC Sigma knees, 3 patients were described to have fractured components at revision, however no further details were given [5].

Fracture of the polyethylene tibial post in posterior stabilised TKA is well documented, in different arthroplasty systems [9-13], including the PFC Sigma [14]. The reasons for the failure of the tibial post has been attributed to component malalignment, inappropriate soft tissue balancing, trauma, dislocation of the implant and component design. Ng and Chiu did report fragmentation of a tibial liner along with tibial post fracture at revision in their case [15].

On a thorough search of the literature no reports of fracture of the anterior locking flange on the tibial surface of a PFC Sigma liner could be found. Failure of this aspect of the liner could have occurred at initial insertion, where impaction of the liner is required to secure it into the tibial tray. This may have accounted for the discomfort this patient reported in the second post-operative year, however this would not explain the regression of these symptoms and several years of a pain free stable TKA. A manufacturing fault could have been to blame; this has been reported previously in the Kinemax Plus knee system [16], where only a 75% implant survival rate at 9 years was found. Conclusions from this study suggested that type 2 fusion defects were present in the ultra high molecular weight polyethylene liners of explanted and unused tibial inserts, resulting in wear, fracture and implant failure. Results were compared with the PFC Sigma TKA where no such problems were found. The fact the articular surfaces of the tibial liner was completely intact and showed no sign of wear in our case, would reduce the possibility of a manufacturing fault in the polyethylene. The insults to the tibial post were likely a result of the femoral component articulating on the subluxed liner. Repetitive stress on the anterior aspect of the liner may have lead to the breakage. Though the cause of this stress is not clear with the gentleman having similar activity levels, mass and range of motion as many following this surgery. Overall the cause of the failure of the anterior locking flange remains uncertain.

Conclusion

We report the first case of a fractured anterior locking flange of a Depuy PFC Sigma TKA, one of the most commonly used prostheses. The patient presented with pain, swelling and instability. Radiographic changes were evident. Revision of the polyethylene liner led to a good outcome. Surgeons and GPs should be aware of this method of failure and consider this diagnosis in a patient presenting with a painful or unstable TKA which was previously doing well.

Clinical Message

Fracture of the anterior locking flange of the Depuy Press-fit Condylar (PFC) Sigma prosthesis should be considered by surgeons assessing a painful or unstable total knee replacement .

References

1. *National Joint Registry for England and Wales: 8th Annual Report 2011.*
2. *Schai PA, Thornhill TS, Scott RD. Total knee arthroplasty with the PFC system. Bone Joint Surg Br 1998;80:850-8.*
3. *Hepinstall MS, Rodriguez JA. Polyethylene subluxation: a radiographic sign of locking mechanism failure after modular total knee arthroplasty. J Arthroplasty 2011;26(1):98-102.*
4. *Asif S, Choon DS. Midterm results of cemented Press Fit Condylar Sigma total knee arthroplasty system. J Orthop Surg 2005;13(3):280-4.*
5. *Dalury DF, Barrett WP, Mason JB, Goldstein WM, Murphy JA, Roche MQ. Midterm survival of a contemporary modular total knee replacement: A multicentre study of 1970 knees. Bone Joint Surg B 2008;*

90-B(12): 1594-6.

6. Clayton RA, Amin AK, Gaston MS, Brenkel IJ. Five-year results of the Sigma total knee arthroplasty. Knee 2006;13(5):359-64.

7. Zaki SH, Rafiq I, Kapoor A, Raut V, Gambhir AK, Porter ML. Medium-term results with the Press Fit Condylar (PFC) Sigma knee prosthesis the Wrightington experience. Acta Orthop Belg 2007;73(1):55-9.

8. Dalury DF, Gonzales RA, Adams MJ, Gruen TA, Trier K. Midterm results with the PFC Sigma total knee arthroplasty system. J Arthroplasty 2008;23(2):175-81.

9. Clarke HD, Math KR, Scuderi GR. Polyethylene post failure in posterior stabilized total knee arthroplasty. J Arthroplasty 2004;19(5):652-7.

10. Chiu YS, Chen WM, Huang CK, Chiang CC, Chen TH. Fracture of the polyethylene tibial post in a NexGen posterior-stabilized knee prosthesis. J Arthroplasty 2004;19(8):1045-9.

11. Lee CS, Chen WM, Kou HC, Lo WH, Chen CL. Early nontraumatic fracture of the polyethylene tibial post in a NexGen LPS-Flex posterior stabilized knee prosthesis. J Arthroplasty 2009;24(8):1292.

12. Mestha P, Shenava Y, D'Arcy JC. Fracture of the polyethylene tibial post in posterior stabilized (Insall Burstein II) total knee arthroplasty. J Arthroplasty 2000;15(6):814-5.

13. Hendel D, Garti A, Weisbort M. Fracture of the central polyethylene tibial spine in posterior stabilized total knee arthroplasty. J Arthroplasty 2003;18(5):672-4.

14. Sands K, Silver J. Fracture of the Polyethylene Tibial Post in a Posterior Stabilized PFC Total Knee Arthroplasty. Orthopaedics 2005; 28: [link]

15. Ng TP, Chiu KY. Recurrent dislocation of total knee arthroplasty: an unusual cause. J Arthroplasty 2003;18(8):1067-70.

16. Reay E, Wu J, Holland J, Deehan D. Premature failure of Kinemax Plus total knee replacements. J Bone Joint Surg Br 2009;91(5):604-11.

Conflict of Interest: Nil
Source of Support: None

How to Cite this Article:
Jeavons R, Dowen D, Rushton P, Ryan D, Gill P. Fracture of the Anterior Locking Flange of A Total Knee Arthroplasty Polyethylene Liner Presenting with Pain following Knee Replacement. Journal of Orthopaedic Case Reports 2014 April-June;4(2): 60-63