



Treatment of Osteoporosis with Antiresorptive agent, Alendronate - warrants careful follow-up

Sumit Kumar Jain¹, Shuvendu Prosad Roy¹, Onkar Nath Nagi¹

ABSTRACT

Introduction: Alendronate is the most popular bisphosphonate used to prevent fragility fracture of postmenopausal osteoporosis. There is common belief among physicians that Alendronates are very safe without many side effects and they continue it for long time. Recent papers have shown that, some patients who are on this drug from a long period suffered a rare type of fracture. We are reporting a similar type of case for the first time from Indian subcontinent but with a different associated medical condition.

Case presentation: A 75 years old female presented with spontaneous fracture of right femur diaphysis. She was on Alendronate for past six years. Her bone metabolic picture also revealed vitamin D insufficiency and secondary hyperparathyroidism.

Conclusion: Alendronate induced atypical fracture in association with secondary hyperparathyroidism is an unusual presentation which has not been reported in any of the case reports till date as per our knowledge. This type of presentation may need future investigation both for disease pathophysiology and future outcome in this type of fracture treatment. Treatment of osteoporosis with antiresorptive agent, alendronate; warrants careful follow-up

INTRODUCTION:

Fractures due to trivial trauma occur commonly in association with osteoporosis around hip followed by vertebral collapse and Colles' fracture [1].

Antiresorptive agents; bisphosphonates (specially Alendronate), are the first choice of drugs commonly used for the treatment of postmenopausal osteoporosis from decades which has reduced the osteoporosis induced fracture by significant amount [2]. Subtrochanteric and diaphyseal areas are considered to be the strongest part of femur and subjected to the highest stresses of the body [3]. Strongest bone of the body; femur diaphysis, is unusual site for fracture due to trivial trauma, raises significant suspicion regarding the pathogenesis of the fracture. In recent years, some cases of subtrochanteric and diaphyseal fracture due to trivial trauma have been reported in association with long term alendronate therapy [4-7]. This pattern of fracture is defined as alendronate induced atypical fracture. To our knowledge, we are presenting a case of similar pattern, first time in Indian subcontinent.

CASE PRESENTATION:

A 75 year old female presented to the emergency department of our hospital with a history of trivial fall at home, after feeling a crack at her right thigh. She was unable to bear weight on her right lower limb. On examination, there was upper thigh tenderness, deformity and crepitus on palpation. Radiograph revealed a transverse fracture at upper mid diaphysis of femur with medial spiking of distal fragment without any lytic area through fracture line (Fig. 1). Unusual mechanism of injury, not related to the site and pattern of fracture warranted the treating surgeon to get a detailed patient history, Radiograph of the opposite femur for correlation, skeletal survey and biological markers of bone to rule out any pathological fracture. After scrutinizing all these, it was found that the patient was taking alendronate for postmenopausal osteoporosis for more than six years. The BMD report, on the basis of which alendronate therapy was started, was not available with the patient. She was never on hormone replacement therapy (HRT) or on steroids. She

¹ Sir Ganga Ram Hospital, New Delhi, India

*Address of Correspondance

Dr. Shuvendu Prosad Roy
M.S. Orthopaedics
Clinical fellow
Joint replacement and Reconstruction Centre
Sir Ganga Ram Hospital
e-mail : roy_sp27@yahoo.co.in



was on regular proton pump inhibitor and ACE inhibitor. Radiograph of left femur showed thickening of lateral cortex with a stress line at the same level as the right one (Fig. 1).

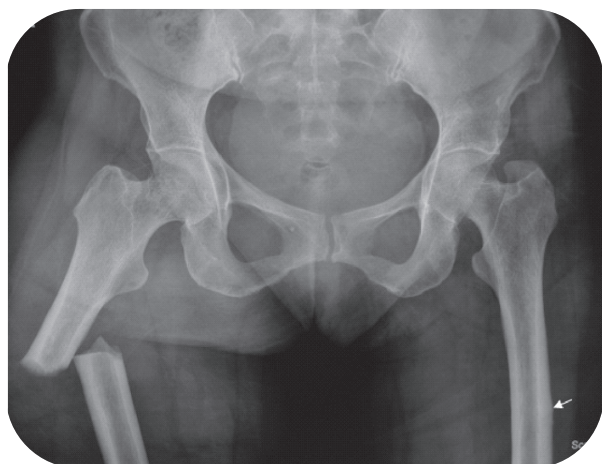


Figure 1 : showing transverse fracture on right side of femur diaphysis with lateral cortical thickening and medial spiking and lateral cortical thickening on left side.

This stress line was confirmed later on bone scan. (Fig. 2) Biochemical and hematological markers were otherwise within normal limit except vitamin-D at a lower range, increased serum parathyroid hormone level, reduced spot calcium in urine and hypocalcaemia (Table 1).

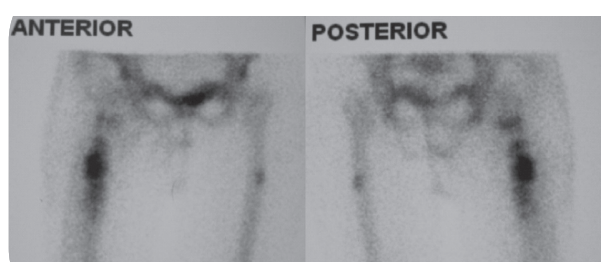


Figure 2 : Bone scan of both lower limbs with pelvis showing increased uptake at lateral cortex of left femur and very high activity at right femur fracture site.

DISCUSSION:

Diagnosis of alendronate induced atypical or insufficiency fracture is concluded by high index of clinical suspicion and is confirmed by typical radiological finding. Clinical presentation includes long term bisphosphonates (alendronate) therapy usually more than five to seven years, spontaneous fracture or fracture on trivial trauma which may

Table 1: Biochemical marker of bone pathology of the patient with reference

Variables	Reff. Value	Patient's value
Serum calcium (mg/dl)	8.2-10.4	7.9
Urinary spot calcium (mg/dl)		<2
Serum Phosphorus (mg/dl)	2.5-4.6	2.4
Alkaline phosphates (IU/L)	39-117	76
Serum 25, Hydroxy Vit. D (ng/dl)	7.6-75	22
Serum Parathormone (pg/dl) ESR	12-72	146

proceed by prodromal pain for few weeks in a relatively young post menopausal woman. Sometimes the fracture occurs on both sides at the same time or in short span of time. The typical radiographic picture includes a) transverse or short oblique fracture at subtrochanteric or diaphysis area of femur, b) medial spiking of distal fragment, c) lateral cortical thickening and d) bilateral identical involvement [5,6]. Pathogenesis is explained by the strong anti-osteoclastic activity of alendronate which produces a severely suppressed bone turnover status (SSBT) but does not inhibit mineralization which in turn produce hyper-mineralized brittle bone [8-10]. Microcracks which results from stress and strain on bone due to day to day activities develop relatively more in hyper mineralized bone and due to SSBT these micro cracks do not heal, so accumulate and ultimately produce a stress zone [11]. When this stress zone becomes weak enough to bear the body weight, the bone fractures spontaneously or with trivial trauma.

Vitamin D insufficiency and increased parathyroid level in this patient raised the suspicion of osteomalacia but radiographic feature (Fig. 1) and biochemical markers (Table 1) did not support this diagnosis rather concluded alendronate induced atypical or insufficiency fracture [12]. Biochemical picture of this patient can be explained by the following hypothesis. Probably alendronate induced inhibition of bone turnover have blocked the skeletal pool of calcium for serum calcium homeostasis. Thus reduced serum Ca+2 together with vitamin D insufficiency might have influenced increased production of parathormone. But this high level of parathormone was not probably sufficient enough to produce high turnover status of bone due to SSBT and serum calcium level was maintained by reducing urinary excretion only.



Alendronate, which is available since 1995 [13], have a better patient compliance as compared to other bisphosphonates available at that time owing to its weekly doses and better gastrointestinal tolerability. It is reasonable to assume that a huge number of people must have been taking this drug for decades but the reported incidence of this clinical condition is less in comparison to the assumed consumption of the drug [14]. The reason behind this may be that many medical practitioners are not aware of this new clinical entity, that is why many cases may not have been diagnosed. Also due to the bizarre bioavailability of alendronate, SSBT may not develop in all those who are taking bisphosphonates for long term.

The socioeconomic and psychological impact of this fracture is huge, as the adynamic status of the bone delays the fracture healing and ultimate mobility of the patient [8]. A frustrating observation of many studies is that this drug is being used indiscriminately without following any standard guidelines [7] which may produce a great impact on healthcare system in future. Strict practice of FRAX [15] may enable the practicing surgeon and physician to prescribe this medicine judiciously. The incidences of this fracture do not outweigh the benefits of bisphosphonates in reducing osteoporosis induced fracture. Therefore it is not justifiable to stop prescribing bisphosphonate for the treatment of osteoporosis. Even radiographic surveillance of all the patients who are using bisphosphonates for long period is not economically feasible.

CONCLUSION:

This is a newly emerging complication of antiresorptive agents and considering the present practice it may come up more adversely in future. It is advisable to deal these patients with more careful and elaborate clinical follow-up. Radiograph to be advised in highly doubtful cases to rule out any SSBT. It may be better to stop these medications once patient achieves normal BMD.

CLINICAL MESSAGE:

when prescribing Alendronate Surgeons must be aware of potential of developing stress fractures on long term use.

EDITORS NOTE

Only pathology was discussed here to highlight this complication due to antiresorptive therapy. Management part was not discussed.

ABBREVIATION:

FRAX- Fracture Risk Assessment Tool, BMD- Bone

Mineral Density

REFERENCES:

1. Cooper C, Melton LJ. Epidemiology of osteoporosis. Trends Endocrinol Metab. 1992; 3: 224.
2. Black DM, Thompson DE, and Bauer DC et al. Fracture Intervention Trial: Fracture risk reduction with alendronate in women with osteoporosis: The Fracture Intervention Trial: FIT Research Group. J Clin Endocrinol Metab 2000; 85: 4118-24.
3. Sims SH. Subtrochanteric femur fractures. Orthop Clin North Am. 2002; 33: 113-126.
4. Goh SK, Yang KY, Koh JS, Wong MK, Chua SY, Chua DT, Howe TS. Subtrochanteric insufficiency fracture in patients on alendronate therapy: a caution. J Bone Joint Surg [Br] 2007; 89-B: 349-53.
5. Kewek EB, Goh SK, Koh JS, Png MA, Howe TS. An emerging pattern of subtrochanteric stress fracture: a long-term complication of alendronate therapy? Injury 2008; 39: 224-31.
6. Neviaser AS, Lane JM, Learth BA, Edobor-Osula F, Lorich DG. Low energy femoral shaft fracture associated with alendronate use. J orthop Trauma. 2008; 22: 346-50.
7. Das De S, Setiobudi T, Shen L, Das De S. A rational approach to management of alendronate related subtrochanteric fractures. J Bone Joint Surg [Br] 2010; 92-B: 679-86.
8. Odvina CV, Zerwek JE, Rao DS, Maalouf N, Gothschalk FA, Pak CYC. Severely suppressed bone turnover: a potential complication of alendronate therapy. J Clin Endocrinol Metab 2005; 90: 1294-301.
9. Bovin G, Meunier PJ. Effects of bisphosphonates on matrix mineralization. J Musculoskeletal Neuronal Interact. 2002; 1: 538-43.
10. Curry JD. Effects of differences in mineralization on the mechanical properties of bone. Philos Trans R Soc Lond B Biol Sci. 1984; 304: 509-518.
11. Stephan JJ, Burr DB, Pavo I, Sipos A, Micoliska D, Li J, FAhrleitner-pammer A, Petto H, Wetmore M, micholsky D, Sato M, Dobing H. Low bone mineral density is associated with bone microdamage accumulation in postmenopausal women with osteoporosis. Bone 2007; 41(3): 378-385.
12. Mcklnna MJ, Kleerkoper M, Ellis BI, et al. Atypical insufficiency fractures confused with loosers zones of osteomalacia. Bone 1987; 8: 71-8.
13. U.S. Food and Drug Administration. Drugs @ FDA. <http://www.fda.gov/forHealthProfessionals/Drugs/default.htm> . Accessed 2010 Nov 7.
14. Shane E, Burr D, Ebeling P R, et al. Atypical Subtrochanteric and diaphyseal femoral fractures: Report of a task force of the American Society for Bone and Mineral Research. Journal of Bone and Mineral Research 2010; 25(11): 2267-2294.
15. No author listed. FRAX: WHO Fracture Risk Assessment Tool. <http://www.shef.ac.uk/FRAX> . Accessed 2010 Nov 7.

Conflict of Interest : NONE
Source of Funding : NONE

