

Giant muscle-skeletal hydatidosis - A clinical dilemma

Arashdeep Singh¹, Harneet Narula¹

ABSTRACT:

Introduction: Though imaging findings of hydatid cyst involving liver, lung and brain have commonly described, description of musculo-skeletal hydatidosis is rare. It is usually a “clinical dilemma” as the lesion often clinically mimics a neoplasm (more so a malignancy) and serological tests for hydatidosis are often negative.

Case Report: We describe a case of unusually giant hydatidosis of left lower limb involving various muscles as well left hemi-pelvis with extremely unusual extension into pelvis. Ultrasognography and CT scans suggested Hydatidosis but serological tests were negative. FNAC confirmed the diagnosis and en bloc resection was done. Follow up medical management was continued with no recurrence at 6 months.

Conclusion: Imaging findings are classical and often solves the clinician’s dilemma and also accurately depict the extent of spread. FNAC may be required to confirm the diagnosis. Enbloc resection and medical management give good result with minimal complications

Keywords: Musculo-skeletal, hydatid cyst, ultrasound, CT, MRI

INTRODUCTION:

Hydatidosis can virtually involve any part of human body, though involvement of liver, lung, brain and heart is common with imaging findings related to these organs being commonly described in literature [1]. Musculo-skeletal involvement of hydatid cyst is extremely rare accounting for 0.7-3% cases of

hydatidosis [1]. Musculo-skeletal involvement of hydatidosis occurs usually from direct implantation of oncospheres and rarely from metastatic dissemination of visceral cyst. We describe a case of giant hydatidosis of musculo-skeletal system involving various thigh muscles with unusual extension into pelvis with destruction of bone.

CASE REPORT

35 year lady presented to surgery department of our hospital with history of swelling over left thigh over long duration which has rapidly increased over a period of last three months. She was afebrile and her vital parameters were normal. On local examination soft tissue mass of size approximately 13x12cms was palpated. It was fixed, tender and showed superficial erythema. Various laboratory investigations including

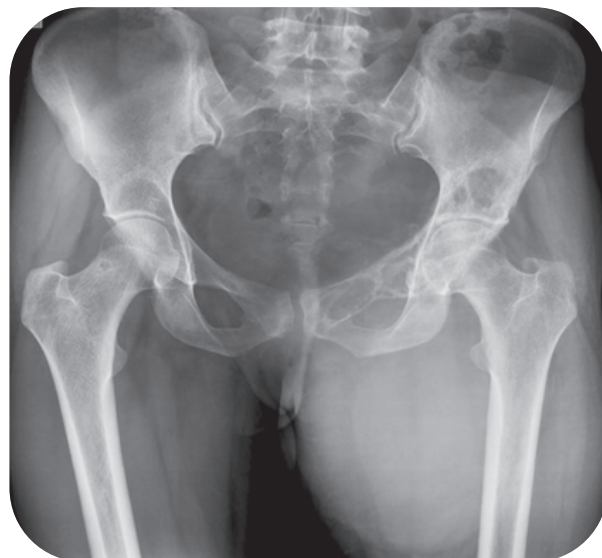

Figure 1 : Conventional AP radiograph of pelvis shows lytic expansile lesions of left hemi-pelvis with associated cortical thinning involving superior pubic ramus, iliac wing and acetabular roof. Large soft tissue swelling showing interspersed foci of calcification is seen in left proximal thigh. Underlying left femur appears normal.

¹ Gian Sagar Medical College, Banur Punjab India

Address of Correspondance

Dr Arashdeep Singh
Gian Sagar Medical College, Banur Punjab India
docrammi@yahoo.co.in

total leucocyte count and differential leucocyte count were within normal limits. Based on clinical findings, provisional diagnosis of “soft tissue sarcoma” was made and patient was referred to “Imaging” department for exact extent of the lesion.

Conventional radiography of pelvis (Anterior posterior view) showed a large soft tissue mass in left medial thigh showing foci of calcification [Fig. 1]. Expansile lytic destruction of left hemi-pelvis was noted predominantly involving superior pubic ramus and acetabular roof. Possibility of “chondroid” tumour was based on radiographic findings. Chest radiograph of the patient was normal.

Ultrasonography of left thigh revealed large multi-cystic mass (cartwheel appearance) and settled echogenic debris (representing daughter cysts and hydatid sand respectively) within involving various muscles of thigh on medial side [Fig. 2]. These

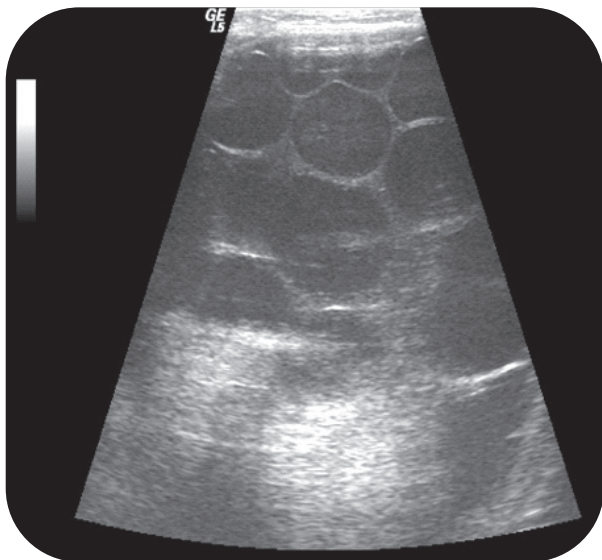


Figure 2 : Ultrasonography shows multi-septated cystic mass in left thigh giving “cart wheel appearance”. These findings are typical for hydatid cyst

imaging features were classical for hydatid cyst. CT scan performed subsequently revealed the size of the lesion which measured approx. 20.6x13.1x11.2cms and was extending into pelvis on left side mildly displacing the urinary bladder towards right side [Fig. 3]. Adductor brevis, adductor longus, pectineus and ilio-psoas muscles of left side were involved by this lesion. Acetabular roof demonstrated pathological fractures with expansile, lytic lesions with associated cortical thinning noted on left superior pubic ramus and of iliac bone [Fig. 3]. Rest of body organs were normal on radiographic screening.

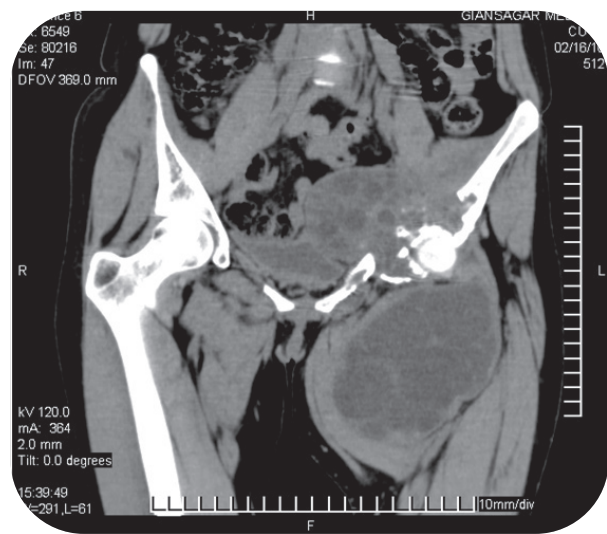


Figure 3 : Coronal reformatted plain CT scan of pelvis and thighs showing huge multi-septated cystic mass involving various medial muscles of thigh showing unusual extension into pelvis on left side with associated destruction of left hemipelvis.

Serological screen for hydatid cyst (including IgE antibody titre for hydatidosis) which were performed subsequently was negative. Due to variability in imaging and serological results, Fine needle aspiration cytology (FNAC) was planned which showed “fragments of hyaline, laminated cyst wall membrane in background of cellular debris” confirming the lesion to be hydatidosis. En bloc resection of hydatid with wide surgical margins was performed without destroying the cyst wall. This was followed by extensive irrigation with hypertonic saline. Patient was put on oral anti-helminthics and is on regular follow up for last six months with no evidence of recurrence.

DISCUSSION:

Human hydatidosis is endemic in Mediterranean basin, Central Asia, East Africa and South America with involvement of lung, liver, spleen, peritoneum, heart and brain being well described. Isolated primary musculo-skeletal hydatidosis is extremely rare as the parasite has to cross the pulmonary and hepatic barriers to reach the muscles [2,3]. High lactic acid levels and contractibility are considered unfavorable for parasite survival [1]. Classically the patient presents with long standing history of lump and muscle fixation, sarcoma often being the first clinical impression.

Imaging plays a pivotal role in diagnosis of hydatid cyst as imaging findings are classical while various serological tests often yield negative results [9].

Ultrasonographic findings of muscular hydatidosis are same as elsewhere with multi-septated cystic mass showing daughter cysts, floating membranes (water-lily sign), calcification and hydatid sand. Bony involvement of hydatid cyst is characterized by expansile lytic lesion with cortical thinning with computed tomography being a better modality than conventional radiography to characterize these findings. It does not show typical "spherical" lesion as pericyst formation does not take place, moreover bone being rigid, cyst usually enlarges in an irregular branching fashion along the path of least resistance [4] as in our case.

MRI is better than other imaging modalities as it gives exact extent of lesion including involvement of various muscles and associated bony destruction [6], hence allowing better surgical planning.

"Enbloc" surgical excision and antihelmenthics form the mainstay of treatment. "Giant hydatid cyst" are difficult to manage due to greater chances of dissemination as well as anaphylactic shock at surgery. Hence the surgeon has to be "mentally prepared" for any inadvertent situation making "pre-operative diagnosis and exact delineation of lesion" a must [7]. Pre-operative medical treatment may sterilize the cyst cavity, hence decreasing chances of intra-operative spillage. Intra-operative irrigation of 0.5% cetrimide, 15% hypertonic saline and 0.5% silver nitrate solution may kill daughter cysts, reducing chances of dissemination and anaphylaxis. Bony pelvis is often difficult location for complete excision of hydatid cysts, hence sub-total excision and joint replacement can also be acceptable option in patients [10] with recurrent disease;. Present imaging technologies (Ultrasound/CT and MRI) by and large solve this problem by not only suggesting the diagnosis but also defining its extent accurately. FNAC may be reserved for limited number of patients where there is discrepancy between imaging and serological results [8] with anti-anaphylactic measures kept ready to manage any inadvertent situation.

CONCLUSION:

Musculo-skeletal hydatidosis is extremely rare and often clinically mimics malignancy. Serological tests are often negative, however imaging findings (ultrasound, CT and MRI) of hydatidosis are typical

thus making "imaging studies" the primary mode of investigating such a disease. An index of suspicion should be kept in mind while evaluating any cystic mass of musculoskeletal origin especially in endemic areas.

CLINICAL MESSAGE:

Musculoskeletal hydatidosis are rare but cystic mass in endemic area should include it in differential diagnosis. USG will clinch the diagnosis and other investigations may be needed to determine the extent of disease. Enbloc resection with post operative medical management gives good results.

REFERENCES:

1. Tatari H, Baran O, Sanlıdağ T, Göre O, Ak D, Manisali M et al. Primary intramuscular hydatidosis of supraspinatus muscle. Arch Orthop Trauma Surg. 2001;121(1-2):93-4
2. García-Alvarez F, Torcal J, Salinas JC, Navarro A, et al. Musculoskeletal hydatid disease: A report of 13 cases. Acta Orthop Scand. 2002; 73(2):227-31
3. Engin G, Acunaş B, Rozanes I, Acunaş G. Hydatid disease with unusual localization. Euro Radiol. 2006 ; 10: 1904-12
4. Polat P, Kantarci M, Alper F, Suma S, Koruyucu MB, Okur A. Hydatid cyst from "head to toe". Radiographics. 2003 Mar-Apr;23(2):475-94
5. Durakbasa CU, Tireli GA, Sehiralti V, Sander S, Tosyali AN, Mutus M. An audit on pediatric hydatid disease of uncommon localization: Incidence, diagnosis, surgical approach and outcome. J Pediatr Surg. 2006 Aug;41(8):1457-63
6. Song XH, Ding LW, Wen H. Bone hydatid cyst. Post grad Med J 2007;83: 536-42
7. Duncan GJ, Tooke SM. Echinococcus infestation of the biceps brachii. A case report. Clin Orthop Relat Res 1990; 261: 247-50
8. Saha A, Paul VK, Kumar K. Diagnosis of Primary hydatid cyst in thyroid by Fine Needle Aspiration Cytology .J Cytol 2007; 24(3):137-39.
9. Arazi M, Erikoglu M, Odev K, Memik R, Ozdemir M. Primary Infestation of the bone & muscles. Clin Orthop Relat Res. 2005;432:234-41
10. Neelapala VS, Chandrasekar CR, Grimer RJ. Revision hip replacement for recurrent hydatid disease of the pelvis: a case report and review of literature. J Orthop Surg Res. 2010 Mar 11;5:17

Conflict of Interest : NONE
Source of Funding : NONE

