

Osteochondroma at its rarest site

Ankur Mittal¹, PSB Srinivasulu¹, Ramprasad R¹, Y Siva Prasad¹

What to Learn from this Article?

A rare presentation of huge calcific mass (osteochondroma) in an elderly female.

Abstract

Introduction: Osteochondromas usually arise from the metaphyseal region of the growing skeleton but extraskeletal cartilaginous tumors are rarest.

Case Report: A 65 year old woman presented with anterior knee pain and inability to flex her knee more than 90° since 1 year. Clinical examination and imaging studies revealed a nodular calcific mass in the anterior portion of the knee i.e. patella. Following excision, histopathology confirmed the diagnosis of extra-osseous osteochondroma-like soft tissue mass, with no recurrence in 36 weeks.

Conclusion: An integrated clinical-pathologic diagnosis helps to clarify the nature of extraskeletal cartilaginous tumors that can arise at unusual anatomic site viz. patella. Complete local surgical excision is the management of choice.

Keywords: osteochondroma, clinical, patella, pathological, excision, extraskeletal cartilaginous.

Introduction

Osteochondromas usually develop in relation to the periosteum, and occur around the growth plate of long bones, especially the knee. The tumor usually stops to grow with closure of the growth plate [1] BUT, some of these tumors continue to grow after skeletal maturity [2] we report a patient with an extra-osseous osteochondroma-like soft tissue mass in the anterior portion of the knee joint.

Case report

65 Years old women presented with one-year history of anterior knee pain and unable to flex knee more than 90 degree. There was no history of trauma, constitutional symptoms, fever, loss of weight,

morning stiffness and involvement of other joints.

Clinical examination shows Firm nodular mass was present in the anterior part of the knee, extending superiorly, inferiorly, medially and laterally as well. There was no joint line tenderness present Range of motion was Flexion was restricted to 90 degree and full extension was possible. Neurovascular examination was normal Serology was normal. Surgical excision of mass was done. Intraoperatively Mass involves complete patella but femoral condyle, tibial condyle and patellar tendon was not involved. Post operatively Recovery was uneventful and patient returned to activity of daily living after 2 weeks. She regained 110 degree of flexion Histopathological examination reveals Osteochondroma features with no evidence of malignancy After 6 months patient

Access this article online

Website:
www.jocr.co.in

DOI:
2250-0685.274

Author's Photo Gallery



Dr. Ankur Mittal



Dr. PSB Srinivasulu



Dr. Ramprasad R



Dr. Y Siva Prasad

¹Mittal Surgical Hospital, Ambala Road, Kaithal – 136027 Hararyana.
²Narayana Medical College and Hospital, Nellore, Andhra Pradesh.

Address of Correspondence

Dr Ankur Mittal
Mittal Surgical Hospital, Ambala Road, Kaithal – 136027 Hararyana.
Email:- mittal.87@gmail.com

Copyright © 2015 by Journal of Orthopaedic Case Reports

Journal of Orthopaedic Case Reports | pISSN 2250-0685 | eISSN 2321-3817 | Available on www.jocr.co.in | doi:10.13107/jocr.2250-0685.274

This is an Open Access article distributed under the terms of the Creative Commons Attribution Non-Commercial License (<http://creativecommons.org/licenses/by-nc/3.0>) which permits unrestricted non-commercial use, distribution, and reproduction in any medium, provided the original work is properly cited.

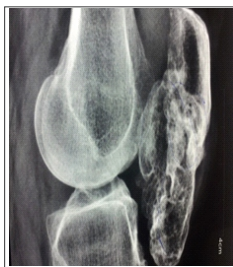

Figure 1: Pre Operative X-Ray

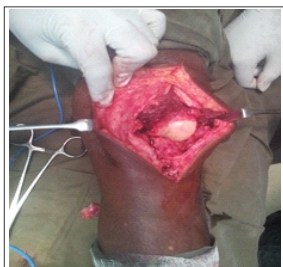

Figure 2: Intraoperative

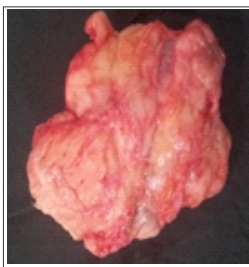


Figure 3: Mass excised

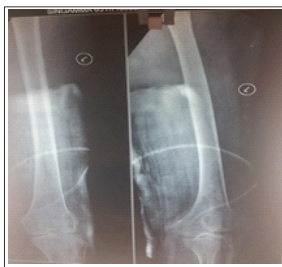


Figure 4: Post Op X-ray

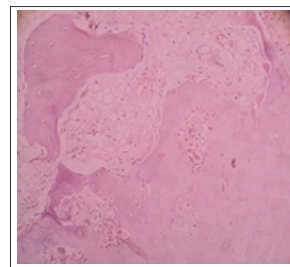


Figure 5: Histopathological picture

was asymptomatic and there was no clinical and radiological evidence of reoccurrence.

Discussion

Large osteochondromas involving the joint capsule or para-articular soft tissues adjacent to a joint are rare osteocartilaginous tumors, first described by Jaffe in 1958 [3]. Subsequently, these lesions have been reported using various terms such as para-articular osteochondroma [4, 5,6], intracapsular chondroma [7], para-articular chondroma [8,9], giant extrasynovial osteochondroma [10], Hoffa's disease [11] and giant intra-articular osteochondroma [12].

But in our case this lesion involve whole of patella that patella cannot be distinguished and at histological examination the mass was characterized by trabecular bone tissue surrounded by hyaline cartilage. The pathogenesis and classification of this lesion are still controversial. Rizzello et al. [6] reported that this tumor seems to originate from a cartilaginous metaplasia of the articular and para-articular connective tissue. Rodriguez- Peralto et al., [7] emphasize a possible metaplastic origin of the tumor, due to a

traumatic event of Hoffa's fat pad. Other authors [10, 13] reported a relation between this type of osteochondroma of the knee and a chronic impingement of the infrapatellar fat pad; they conclude that this lesion is the end-stage of Hoffa's disease. But in our case there was no history of trauma or symptomatic history of infrapatellar fat pad. Usually after fusion of epiphysis chances of osteosarcoma is more but in this case at the age of 65yrs no signs of malignancy were seen.

Conclusion

An integrated clinical-pathologic diagnosis helps to clarify the nature of extra skeletal cartilaginous tumors that can arise at unusual anatomic site. Complete local surgical excision is the management of choice with proper follow up for reoccurrence.

Clinical Message

Unusual site of any tumor should be discussed clinically, radiological and pathologically before deciding treatment.

Reference

- Kienbock R: Über die Gelenkscapsel-Osteome. Kniegelenk Fortschr Röntgenstr 1924, 32:527-546.
- Reith JD, Bauer TW, Joyce MJ: Paraarticular osteochondroma of the knee. Report of 2 cases and review of the literature. Clin Orthop 1997, 334:225-232
- Jaffe HL. Tumors and tumorous conditions of the bones and joints. Philadelphia, Lea and Febiger 1958; 558-567.
- Milgram JW, Dunn EJ. Para-articular chondromas and osteochondromas: a report of three cases. Clin Orthop Relat Res 1980; (148): 147-51.
- Reith JD, Bauer TW, Joyce MJ. Paraarticular osteochondroma of the knee: report of 2 cases and review of the literature. Clin Orthop Relat Res 1997; (334): 225-32.
- Rizzello G, Franceschi F, Meloni MC, et al. Para-articular osteochondroma of the knee. Arthroscopy 2007; 23(8): 910.e1-4.
- Rodriguez-Peralto JL, Lopez-Barrea F, Gonzalez-Lopez J. Intracapsular chondroma of the knee: an unusual neoplasm. Int J Surg Pathol 1997; 5(1&2): 49-54.
- Sakai H, Tamai K, Iwamoto A, Saotome K. Para-articular chondroma and osteochondroma of the infrapatellar fat pad: a report of three cases. Int Orthop 1999; 23(2): 114-7.
- Schmidt-Rohlfing B, Staatz G, Tietze L, Ihme N, Siebert CH, Niethard FU. Diagnosis and differential diagnosis of extraskeletal, para-articular chondroma of the knee. Z Orthop Ihre Grenzgeb 2002; 140(5): 544-7.
- Turhan E, Doral MN, Atay AO, Demirel M. A giant extrasynovial osteochondroma in the infrapatellar fat pad: end stage Hoffa's disease. Arch Orthop Trauma Surg 2008; 128(5): 515-9.
- Krebs VE, Parker RD. Arthroscopic resection of an extrasynovial ossifying chondroma of the infrapatellar fat pad: end-stage Hoffa's
- Sarmiento A, Elkins RW. Giant intra-articular osteochondroma of the knee. J Bone Joint Surg Am 1975; 57(4): 560-1.
- Nouri H, Ben Hmida F, Ouertatani M, Bouaziz M, Abid L, Jaafoura H, Zehi K, Mestiri M. Tumour-like lesions of the infrapatellar fat pad. Knee Surg Sports Traumatol Arthrosc 2010; 18(10): 1391-4.

Conflict of Interest: Nil
Source of Support: None

How to Cite this Article

Mittal A, Srinivasulu PSB, Ramprasad R, Siva Prasad Y. Osteochondroma at its rarest site. Journal of Orthopaedic Case Reports 2015 April-June; 5(2): 53-54