

Delayed Case of Congenital Bilateral Trigger Thumb: A Case Report and Review of Literature

Y Bhanu Rekha¹

What to Learn from this Article?

Surgical approach to delayed case of congenital trigger thumb

Abstract

Introduction: Congenital trigger thumb is an uncommon anomaly of children. Its management is controversial, ranging from observation to extensive surgical release. We report a case of delayed presentation of bilateral trigger thumb along with a brief review of past literature.

Case Report: A six year old girl presented with fixed flexion deformity of interphalangeal joints of both thumbs and Notta's nodules. It is diagnosed as trigger thumb and release of bilateral A1 pulleys is done. But we found another constricting annular pulley just distal to A1. Only after splitting the distal pulley, we could get complete extension of interphalangeal joints. At two years follow-up, the child is free of complications.

Conclusion: Splitting of A1 pulley alone may not be sufficient in few cases of trigger thumb which may require distal release too

Keywords: Congenital trigger thumb, bilateral trigger thumb and variable pulley of thumb.

Author's Photo Gallery



Dr. Y Bhanu Rekha

Introduction

Congenital trigger thumb is a rare anomaly found in children. It is observed in approximately 3.3 infants out of 1000 [11].

Trigger thumb is due to stenosing tenosynovitis of Flexor Pollicis Longus at the level of first annular pulley. The tendon also shows corresponding thickening called Notta's nodule just proximal to the stenosis in the sheath. Because of these, child develops triggering, pain and later flexion deformity of interphalangeal (IP) joint of the thumb. If these are neglected, child may develop metacarpophalangeal joint (MCP) laxity with hyperextension deformity. If the joint laxity is not diagnosed and corrected, it will be exacerbated post-operatively. [7]

Conservative treatment is tried between 0-3 yrs, with observation alone [12] or with stretching exercises and splints [13]. Surgery is recommended if the child presents after three years of age or if conservative treatment fails. Surgery is not preferred in children aged less than one year as rate of recurrence is higher with surgical release at this age [1]. Good results are obtained if surgery is done in children below four years.

Release of A1 pulley alone is sufficient to relieve the trigger thumb in most of the patients. But in some children, another constricting annular pulley (Av) may be present just distal to A1. It should be identified and split to attain complete extension of the IP joint [8,14].

We present a case of bilateral trigger thumb in a child of six years in whom splitting of A1 and Av pulleys is required to release the constriction.

Case Report

A six year old female child was brought by her parents with flexion

¹Department of Orthopaedics, Dr.Pinnamaneni Siddhartha Institute of Medical Sciences – Research Foundation Chinoutpally, Gannavaram. Andhra Pradesh. India.

Address of Correspondence

Dr Y Bhanu Rekha, Associate Professor,
Department of Orthopaedics, Dr.Pinnamaneni Siddhartha Institute of Medical Sciences – Research Foundation Chinoutpally, Gannavaram. Andhra Pradesh. India.
Email: nbrekha226@gmail.com.
Phone: 9493205542

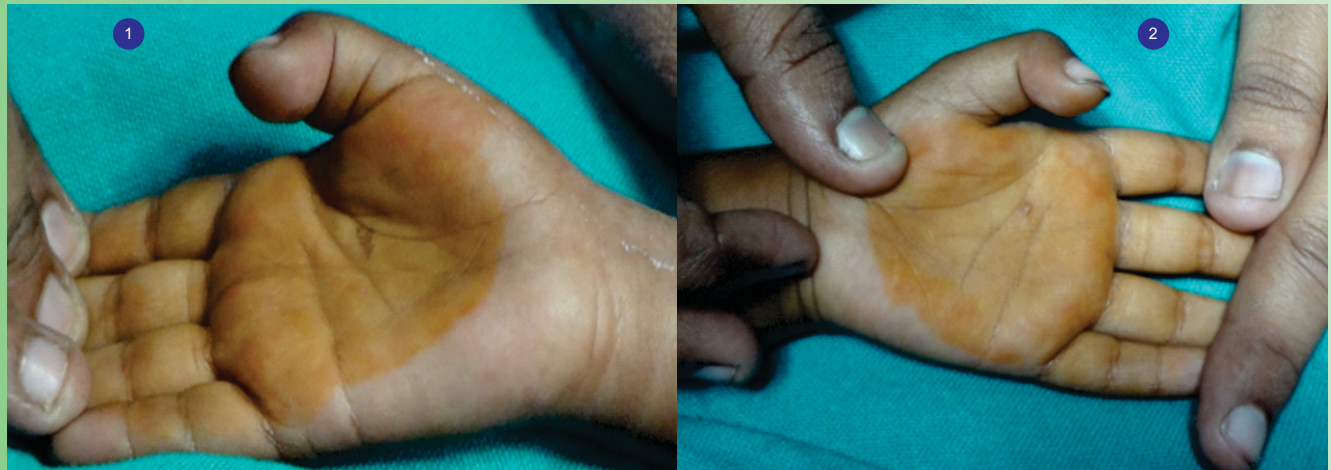

Figure 1,2: Pre-operative flexion deformity of both thumbs

deformity of both the thumbs. The deformity was noticed when the child was six months old, but the finger could be extended to the neutral position at that time. Since one year, extension has not been possible and the finger becomes painful if it is tried. The child did not have any other anomaly. There was no history of trigger thumb in maternal or paternal families.

On examination, IP joints were in 40° of fixed flexion. A 2*2 cm tender nodule was found at the crease of MCP joint. There was no triggering, but minimal extension at IP joint was possible when thumb was flexed at MCP joint. There was no associated MCP joint laxity. Both thumbs presented with similar findings. Figs 1, 2 - The child was diagnosed of having bilateral trigger thumb. Surgical management was decided upon. Under General anaesthesia, with tourniquet applied to the arm, transverse skin incision was made opposite the MCP joint crease. Neurovascular bundles were retracted on either side. The thickened A1 pulley was split longitudinally. But full extension of IP joint could not be achieved. Another constricted annular pulley was found just proximal to A1. It too was released, and IP joint was completely extended. The nodular thickening of FHL was left undisturbed. Fig 3 - Complete active extension of IP joint was possible post-operatively, but the joint tended to be in flexed position. A removable extension splint was given and the patient was asked to do active finger movements atleast thrice a day after removing the splint. The deformity subsided after two weeks and the splint was removed. Neurovascular function was intact. Figs 4,5 - After two months of physiotherapy, the patient had following movements:

Right	Left
MCP 10°-50°	20°-45° (20° of hyperextension to 45° of flexion).
IP 15°-60°	10°-70°

Patient has minimal restriction of IP joint flexion of right thumb and minimal MCP joint hyperextension of left thumb. The child is followed for two years during which she did not develop any complication. There is no functional impairment.

Discussion

The term 'congenital trigger thumb' is thought to be a misnomer by many surgeons, as the condition is almost never seen at birth. Since it develops later, they termed it as 'developmental trigger thumb'[2]. But trigger thumb is reported in twins and siblings, supporting the congenital aetiology to some extent[5,6]. The child in our case apparently developed the deformity at six months of age.

The aetiology of trigger thumb is not well understood. The stenosed sheath and Notta's nodule are biopsied earlier, but no definite pathology can be established [6]. We haven't taken biopsy from either site.

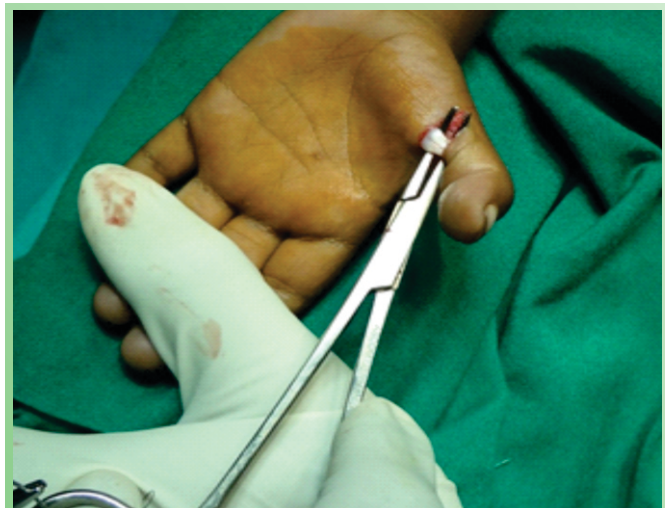

Figure 3: Stenosis of the flexor sheath.

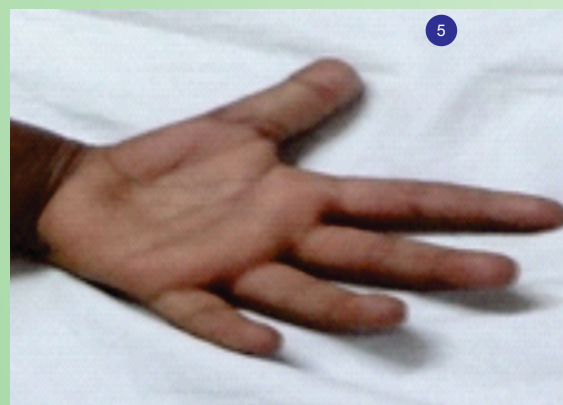
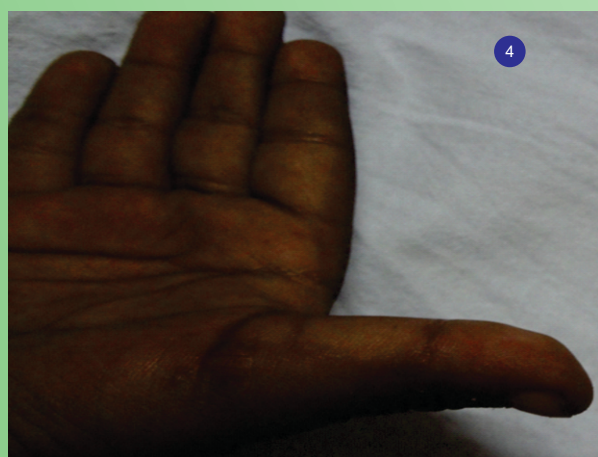

Figure 4, 5: Two weeks after surgery. Flexion deformity was completely corrected.

Trigger thumb is graded by few authors[4].

0A - A Notta's nodule is palpable, but no triggering is observed. Extension of IP joint beyond 00 is possible.

0B - IP joint cannot be extended beyond 00.

Gr.I - The child can actively extend his thumb with triggering.

Gr.II - Active extension is not possible and triggering is observed during passive extension of IP joint.

Gr.III - IP joint is in fixed flexion deformity.

Management of trigger thumb is controversial. In a study of the treatment of trigger thumb, R.A.Dunsmuir et al showed 11% of trigger thumbs referred to them had spontaneous recovery[1]. Baek GH et al reported spontaneous recovery in 63% of patients[12]. Lee ZL et al showed passive stretching exercises and splinting to be effective than observation alone[4,13]. But some surgeons do not find observation or stretching exercises to be effective and they proceeded to surgery in all their patients[2,9]. Surgery is recommended after the child attains one year if

a) conservative management for three months does not show any improvement.

b) flexion deformity of the finger is present[4]

c) the child is older than three years

d) the pathology is bilateral.

Since the child in our case is six years old and she has Gr.IV deformity, conservative management is not tried.

In long standing cases, flexion deformity of IP joint may lead to MCP joint laxity and hyperextension. It is corrected by advancement of MCP volar plate and temporary pinning of MP joint[7]. If it is not identified and corrected, MCP joint laxity will be exacerbated. There is no MCP joint laxity in our case.

Horizontal incision over MCP joint crease is preferred by

many surgeons, but few advocated longitudinal incision to prevent neurovascular injury. But if the neurovascular structures are properly isolated and protected, the incidence of injury is found to be very less, even with the horizontal incision. The scar of vertical incision will be unsightly to the patients in later life.

Stenosis is confined to A1 pulley alone in most children. But occasionally, another annular pulley (Av) is present between A1 and oblique pulleys. It too may be stenosed and unless it is split, patients will have recurrence of trigger thumb[8,14]. In our case, splitting of A1 and Av pulleys bilaterally is required to get full extension of IP joint.

Adequate care should be taken to prevent splitting of the oblique pulley. If it is cut along with A1, bowstringing of Flexor Pollicis Longus will result, causing decreased IP joint flexion [10].

Even though complete active and passive extension are possible post-operatively, thumbs tended to be in flexion of approximately 20° because of long standing deformity. It was corrected with extension splinting for two weeks.

Percutaneous release of A1 pulley is also advocated, but the risk of damaging digital nerves is high.

Phalangeal osteotomy may also be required if the child has flexion deformity of IP joint for 10 years or above[2].

Recurrence of trigger thumb is noted in 4% of children, especially if the child is aged less than one year. It is due to inadequate release of the pulley in the small thumb[1,3].

Conclusion

1. Trigger thumb release in older children can be done effectively if complications are anticipated and looked for.
2. Release of A1 pulley alone may not be sufficient in every case. If the triggering is not resolved with the transection

A1 pulley, other sites of constriction should be explored.

Clinical Message

Delineation of anatomy of pulleys is important in a case of trigger thumb to get complete release and to prevent bowstringing of Flexor Pollicis Longus.

References

1. R.A.Dunsmuir, D.A.Sherlock. The outcome of treatment of trigger thumb in children. *J Bone Joint Surg [Br]* 2000;82-B:736-738.
2. Mustafa Aherdem, Huseyin Bayram, Emre Togrul, Yaman Sarpel. Clinical analysis of the trigger thumb of childhood. *The Turkish Journal of Orthopaedics* 2003;45:237-239.
3. OY Leung, FK Ip, TC Wong, SH Wan. Trigger thumbs in children: Results of surgical release. *Hong Kong Med J* October 2011;17-5:372-375.
4. Jung HJ, Lee TS, Song KS, Yang TT. Conservative treatment of pediatric trigger thumb: Follow-up for over 4 years. *J Hand Surg Eur Vol.* 2012 Mar;37(3):220-4.
5. Masud, Macnicol. A case report of congenital trigger thumb. *JK-PRACTITIONER* 2004; Vol.II No.1:54-55.
6. Rafid Kakel, Pieter Van Heerden, Barry Gallagher, Andrew Verniquet. Pediatric Trigger Thumb in Identical Twins: Congenital or Acquired? *Orthopaedics* 2010 March;33(3).
7. Zhongyu Li, Ethan R. Wiesler, Beth P. Smith, L. Andrew Koman. *Surgical Treatment of Pediatric Trigger Thumb with Metacarpophalangeal Hyperextension Laxity.* *Hand (N Y)*. 2009 December;4(4):380-384.
8. Van Loveren M, vander Biezen JJ. The congenital trigger thumb: is release of the first annular pulley alone sufficient to resolve the triggering. *Ann Plast Surg* 2007 March;58(3):335-7.
9. Ger E, Kupcha P, Ger D. The management of trigger thumb in children. *J Hand Surg Am* 1991 Sep;16(8):944-7.
10. Zissimos AG, Szabo RM. Biomechanics of the thumb flexor pulley system. *J Hand Surg Am.* 1994 May;19(3):475-7.
11. Noriaki Kikuchi, Toshihiko Ogino. Incidence and Development of Trigger Thumb in children. *The Journal of Hand Surgery Apr* 2006; 31(4):541-543.
12. Back GH, Kim JH, Chung MS, Kang SB, Lee YH. The natural history of pediatric trigger thumb. *J Bone Joint Surg Am* 2008 May; 90(5):980-5.
13. Lee ZL, Chang CH, Yang WY, Hung SS, Shih CH. Extension splint for trigger thumb in children. *J Pediatr Orthop.* 2006 Nov-Dec; 26(6):785-7.
14. Manuel F. Schubert, MS, Vanden S. Shah, BS, Clifford L. Craig, MD, John L. Zeller, MD, PhD. Varied anatomy of the thumb pulley system: Implications for successful Trigger thumb Release. *Journal of Hand Surgery Nov* 2012; Vol 37(11): 2278-2285.

Conflict of Interest: Nil
Source of Support: None

How to Cite this Article:

Rekha YB. Delayed Case of Congenital Bilateral Trigger Thumb: A Case Report and Review of Literature. *Journal of Orthopaedic Case Reports* 2014 Jan-Mar;4(1): 24-27