

Neglected Foreign Body, the Cause of Navicular Osteomyelitis in A Paediatric Foot: A Case Report

Chandrashekara C.M¹, George M.A¹, Bader Said Khamis Al-Marboi¹

What to Learn from this Article?

*Foreign bodies can get infected and cause osteomyelitis even after considerable duration after primary trauma
Ultrasound can be used effectively to diagnose radiopaque foreign bodies in cases of osteomyelitis*

Abstract

Introduction: Foreign body injuries with date thorns, metal and wooden splinters are common in Middle East region, as most of it is desert. Some of the injuries lead to cellulitis or abscess formation, if neglected or improperly managed results in osteomyelitis or septic arthritis of foot structures. This is the first report of isolated navicular osteomyelitis following neglected foreign body in a paediatric foot.

Case Report: A 10 year old male patient presented with discharging sinus in left mid-foot 3 years after penetrating injury with wooden splinter. The diagnosis of navicular osteomyelitis is confirmed with plain radio-graphs. The ultrasound of foot was done to localize the foreign bodies. Patient was treated with complete removal of foreign body (wooden splinters), surgical debridement and combination of IV and oral cloxacillin for period of 6 weeks. At 18 months follow up, patient had painless foot with no recurrence or collapse of navicular bone.

Conclusion: The neglected foreign body can result in osteomyelitis of small bones of foot in pediatric patient. The ultrasound is more useful tool in localizing foreign bodies; those are not radio-opaque. Early and prompt diagnosis with adequate treatment of established osteomyelitis by complete removal of foreign body, curettage and antibiotics can give good results.

Keywords: Osteomyelitis; Navicular bone; Foreign body; Paediatric

Author's Photo Gallery



Dr. Chandrashekara
C.M



Dr. George M.A



Dr. Bader Said Khamis
Al-Marboi

Introduction

The majority of Oman is geographically a desert and 25% of children account for total population residing in suburban, rural areas and most walk with open foot wear for daily activities. Thus they are exposed to wide range of injuries from simple puncture wounds to complete penetration caused by date thorns and wooden splinters. The significant numbers of injuries are minor and cause short-term discomfort. However most of the patients rarely seek medical attention.

Most of deep seated infections of structures of foot reported in literature are commonly due to prick injuries related to thorns, nails. However, no case of isolated osteomyelitis of navicular bone caused by neglected foreign body has been reported in literature. Most of isolated cases are primary acute or subacute osteomyelitis. Late presentation can be possible in Middle East countries due to negligence of patients. Pain and inability to bear weight are the main concerns of the affected patient, as the mobility is impaired

¹Department of Orthopedic Surgery. Al-Buraimi Hospital. Sultanate of Oman.

Address of Correspondence

Chandrashekara C.M

Department of Orthopedic Surgery. Al-Buraimi Hospital. Sultanate of Oman

E-mail- drshekar76@rediffmail.com

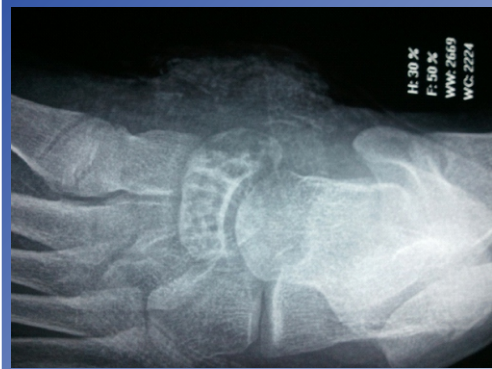

Figure 1: Pre-op X-ray: showing osteolytic lesion involving navicular bone with intact cortex

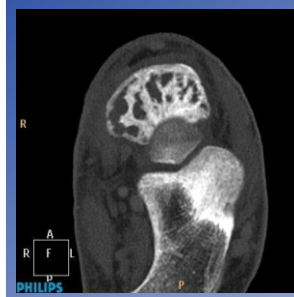


Figure 2: Pre-Op CT scan: showing multiple osteolytic lesions involving whole of navicular bone without involving adjacent joints

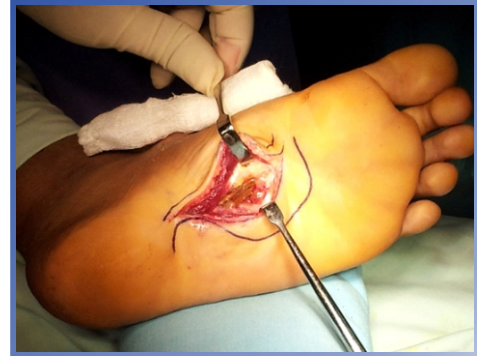


Figure 3 : Plantar "lazy S incision" over medial aspect of foot, exposing wooden splinters

Case Report

We present a previously healthy 10 year old boy, presented with history of on and off pain in the left foot for 3 months duration. He was treated with analgesics and observation. Later, patient presented with swelling in the foot, which progressed to rupture. On further evaluation into past history, he gives history of penetrating injury with wooden splinter 3 years back.

On presentation, there was discharging sinus over medial border of mid foot corresponding to navicular bone with mild swelling and tenderness over plantar aspect without any antecedent systemic symptoms. Plain x-rays revealed multiple osteolytic lesions involving the navicular bone with osteoporosis and intact articular surface without collapse (Fig. 1). His laboratory values were within normal limits. Pre-operative ultrasound suggested fragments of foreign body with surrounding collection on plantar aspect of mid-foot. CT-scan was done rule out adjacent bone involvement (Fig.2)

Surgical exploration was done through two incisions. Through plantar incision, the wooden splinters with

surrounding pockets of frank pus drained from deeper layer of foot and sent for cultures (Fig. 3). There was sinus tract lined by granulation tissue extending from wooden splinter (foreign body) to the exterior on medial aspect on navicular bone perforating the bone itself. The sinus tract was excised completely through the medial incision (Fig 4) and wooden splinters were removed (Fig. 5). Navicular bone was curetted with small dental bur and debridements of wounds were done through the medial incision. The wounds were closed over suction drains. Patient was prescribed initial 2 weeks of IV cloxacillin followed 4 weeks of oral cloxacillin, as the pus culture yielded staphylococcus aureus sensitive to cloxacillin. Fungal culture was negative. Biopsy showed inflamed granulation tissue and foci of granulomatous inflammation. The foot was protected in plaster and non weight bearing for period of 10 weeks. Patient recovered well with no recurrence or collapse at 18 months follow-up.

Discussion

Foreign body penetration injuries are very much common

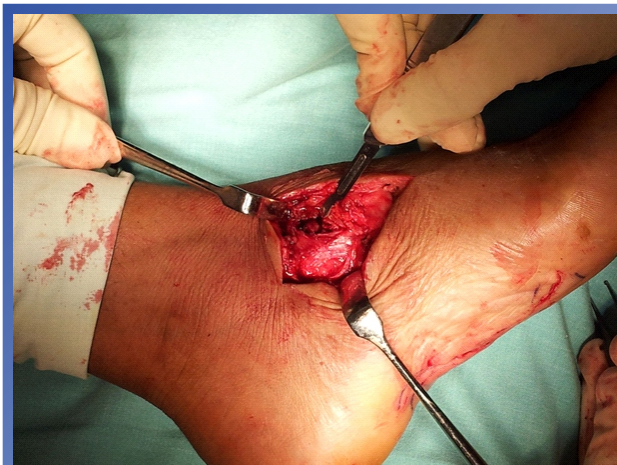

Fig 4 : Second incision over medial aspect of midfoot including sinus



Fig 5 : The removed specimen of wooden splinters

in Middle East region especially in children. Foreign bodies can be retained for a significant time before diagnosis, as high as 15 years [1]. In our case, the wooden splinter remained asymptomatic for three years. An unrecognized foreign body may be focus of acute or chronic infection [2]. The majority of osteomyelitis of paediatric foot bones are either primary or haematogenous in origin, mainly involving calcaneum, talus, navicular, cuboid and metatarsal bones [3]. Most common organisms were *Staphylococcus aureus* or Group A *Streptococcus* [4]. However, *Pseudomonas* is common organism found in deep infection following plantar punctured wounds [5]. To the best of our knowledge, this is the first report of neglected foreign body as the cause of isolated navicular osteomyelitis in pediatric foot.

This patient presented with discharging sinus 3 years after penetrating injury with wooden splinter. Delayed presentation is a significant marker for deep-seated infection. Further infection or relapse after initial improvement suggests the presence of osteomyelitis or a retained foreign body [6]. Patient did not have any comorbid conditions. Clinical signs were minimal compared to early presentation of patients with osteomyelitis. Since much of the spreading foot sepsis from puncture wounds is deep to the deep fascia, and because the sole of the foot has thick skin and subcutaneous fibrous septae, crepitus is not as easily appreciated as it is at other sites. Also the rubor of the inflammatory response is minimal in subfascial sepsis and it is therefore easy to underestimate the extent of deep gangrene [7].

Most of foreign bodies initiate a low grade inflammatory activity without causing infection. However, this patient had frank pus intra-operatively. Patient had radiological evidence of osteomyelitis. Ultrasound is more useful tool in localizing foreign bodies; those are not radio-opaque, especially when there is lack of MRI facility. However, ultrasound, computed tomography or magnetic resonance imaging should be considered for initial evaluation of these patients with penetrating injuries [8]. The CT scans correctly predicted the presence or absence of osteomyelitis and proved helpful in evaluating foot problems [9]. In our case, we did not do either MRI or bone scan for better evaluation of pathology. In countries with limited resources, the emphasis should be on clinical assessment for diagnosis, and good surgical technique for treatment [10].

Patient responded well for period of 6 weeks of cloxacillin. At 18 months follow up, patient had painless foot without

recurrence and collapse of navicular bone. The complete removal of foreign body, debridement and curettage was the key to successful treatment.

Conclusion

The neglected foreign body in pediatric foot can result in osteomyelitis. Ultrasound is more useful tool in localizing foreign bodies; those are not radio-opaque. Early and prompt diagnosis with adequate treatment of established osteomyelitis by complete removal of foreign body, curettage of bone and antibiotics can give good results.

Clinical Message

The neglected foreign body penetrating injuries to foot can result in osteomyelitis. With prompt diagnosis and treatment good results can be achieved.

References

1. Erik R, Bergquist J, Wu S, Jaffery D, Goldsmith M, Anderson L; *Orthopaedic Case of the Month: Ankle pain and swelling in a 23 year old Man; Clin Orthop Relat Res.* 2010; 468(9): 2556–2560.
2. Greene WB. *Unrecognized foreign Body as a focus for Delayed Serratia marcescens Osteomyelitis and Septic Arthritis. Two case reports. J Bone Joint Surg Am.* 1989 Jun; 71(5):754-7.
3. Cakmak Celik F, Sayli TR, Ocquder DA, Bozkurt M, Okdemir D. *Primary subacute Salmonella osteomyelitis of the navicular bone in a child with normal immunity. J Pediatr Orthop B.* 2009 Sep; 18(5):225-7.
4. Jenzri M, Safi H, Nessib MN, Smida M, Jalel C, Ammar C, Ben Ghachem M. *Hematogenous osteomyelitis of the calcaneus in children: 26 cases. [Article in French]. Rev Chir Orthop Reparatrice Appar Mot.* 2008 Sep; 94(5):434-42.
5. Das De S, McAllister TA. *Pseudomonas osteomyelitis following puncture wounds of the foot in children. Injury.* 1981 Jan; 12(4):334-9.
6. Eidelman M, Bialik V, Miller Y, Kassis I. *Plantar puncture wounds in children: analysis of 80 hospitalized patients and late sequelae. Isr Med Assoc J.* 2003 Apr; 5(4):268-71.
7. Naraynsingh V, Maharaj R, Dan D, Hariharan S. *Puncture wounds in the diabetic foot: importance of X-ray in diagnosis. Int J Low Extrem Wounds.* 2011 Jun; 10(2):98-100.
8. Imoisili MA, Bonwit AM, Bulas DI. *Toothpick puncture*

injuries of the foot in children. Pediatr Infect Dis J. 2004 Jan; 23(1):80-2.

9. Williamson BR, Teates CD, Phillips CD, Croft BY. *Computed tomography as a diagnostic aid in diabetic and other problem feet. Clin Imaging. 1989 Jun; 13(2):159-63.*

10. Vidyadhara S, Rao SK. *Thorn prick osteomyelitis of the foot in barefoot walkers: a report of four cases. J Orthop Surg (Hong Kong). 2006 Aug; 14(2):222-4.*

Conflict of Interest: Nil
Source of Support: None

How to Cite this Article:

Chandrashekara CM, George MA, Bader SK. Neglected Foreign Body, the Cause of Navicular Osteomyelitis in A Paediatric Foot: A Case Report. *Journal of Orthopaedic Case Reports* July-Sep 2013; 3(3):26-29