Case Report | Journal of Orthopaedic Case Reports 2020 October: 10(7):Page 44-48

Osteosynthesis in Neglected Femoral Neck Fracture in an Adolescent by Internal Fixation Alone – A Case Report

M I Rayeez Ahmed[1], K R Tarun Prashanth[1]

Learning Point of the Article:

In neglected neck of femur fracture in young adults, not to primarily attempt arthroplasty and to always attempt osteosynthesis.

Abstract

Introduction: Femoral neck fractures are less frequent in adolescents. A neglected femoral neck fracture is one in which there has been a delay of more than 30 days from seeking medical attention from the time of injury [1]. The main complications are non-union and avascular necrosis (AVN) of femoral head. Various methods have been tried to successfully manage neglected femoral fractures.

Case Report: A 16-year-old boy presented with complains of pain over the right hip and inability to walk for the past 3 months, following a history of fall from a height of around 6 ft. He underwent native splinting from an indigenous native bone setter for 3 months. The splint was removed after 3 months, but the symptoms did not subside. He was diagnosed to have neglected femoral neck fracture and underwent open reduction and internal fixation with three 6.5 mm cannulated cancellous screws with washers. There were no post-operative complications. The patient recovered well. At 15 months follow-up, no clinical or radiological signs of AVN were observed with excellent functional outcome.

Conclusion: The incidence of neglected femoral neck fractures is declining with improving health-care facilities in developing countries like India. Accurate anatomical reduction and internal fixation are important to reduce the incidence of AVN and non-union after a femoral neck fracture. Internal fixation of the fracture following valgus osteotomy is the most quoted technique in the literature.

Keywords: Femoral neck, neglected fracture, avascular necrosis, non-union.

Introduction

Femoral neck fractures are less frequent in adolescents. High-energy trauma, road traffic accidents, and falls from height are the most common causes of injury in young adults and children. In developing countries, the fracture often remains untreated as they do not seek treatment due to financial constrains or they may be treated by indigenous native bone setters.

Neglected femoral neck fractures in young adults are challenging to treat because of higher incidence of AVN and non-union. While there is no defined lag period for such a fracture to be called as "neglected," Myers et al. [1] introduced the term "neglected" to indicate a delay of 30 days or more from the injury to seek medical help. In children and young adults, it is almost always indicated to salvage the femoral head because their lifestyle and religious customs require them to squat and sit in a cross-legged position. The extreme degree of movement at the hip required for these postures is not possible with replacement arthroplasty because of long-term loosening [2]. Various techniques have been tried to successfully manage neglected femoral neck fractures.

Case Report

A 16-year-old student presented with complaints of pain over the right hip and inability to walk for 3 months, following a history of fall from a height of around 6 ft. Following the trauma, he was initially taken to a nearby clinic where a radiographic evaluation showed right hip neck of femur fracture (Fig. 1) and he was advised to undergo surgical fixation for the same at a

Access this article online

Website: www.jocr.co.in

DOI: 10.13107/jocr.2020.v10.i07.1912

Author's Photo Gallery

Dr. M I Rayeez Ahmed

Dr. K R Tarun Prashanth

[1]Department of Orthopedic Surgery, Sri Ramachandra Medical College and Research Institute, Sri Ramachandra Institute of Higher Education and Research, Porur, Chennai, Tamil Nadu, India.

Address of Correspondence:
Dr. M I Rayeez Ahmed,
Department of Orthopaedic Surgery, Sri Ramachandra Medical College and Research Institute, Sri Ramachandra Institute of Higher Education and Research, Porur, Chennai - 600 116, Tamil Nadu, India.
E-mail: ahmed.in.141@gmail.com

Journal of Orthopaedic Case Reports | pISSN 2250-0685 | eISSN 2321-3817 | Available on www.jocr.co.in | doi:10.13107/jocr.2020.v10.i07.1912

Figure 1: Radiograph at the time of trauma.

Figure 2: Radiograph at presentation.

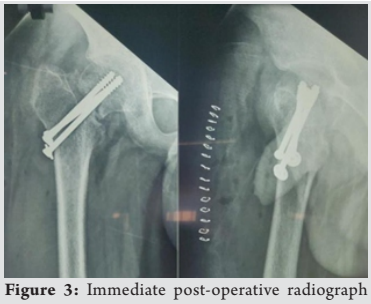

Figure 3: Immediate post-operative radiograph showing internal fixation of neck of femur.

higher center. However, he was not willing and underwent native splinting from an indigenous native bone setter.

Harris Hip Score

Hip ID:
Study Hip: ☐ Left ☐ Right
Examination Date (MM/DD/YY): / /
Subject Initials: |___|___|___|
Medical Record Number:

Interval: _____

Harris Hip Score

Pain *(check one)*
- ☐ None or ignores it (44)
- ☐ Slight, occasional, no compromise in activities (40)
- ☐ Mild pain, no effect on average activities, rarely moderate pain with unusual activity; may take aspirin (30)
- ☐ Moderate Pain, tolerable but makes concession to pain. Some limitation of ordinary activity or work. May require Occasional pain medication stronger than aspirin (20)
- ☐ Marked pain, serious limitation of activities (10)
- ☐ Totally disabled, crippled, pain in bed, bedridden (0)

Limp
- ☐ None (11)
- ☐ Slight (8)
- ☐ Moderate (5)
- ☐ Severe (0)

Support
- ☐ None (11)
- ☐ Cane for long walks (7)
- ☐ Cane most of time (5)
- ☐ One crutch (3)
- ☐ Two canes (2)
- ☐ Two crutches or not able to walk (0)

Distance Walked
- ☐ Unlimited (11)
- ☐ Six blocks (8)
- ☐ Two or three blocks (5)
- ☐ Indoors only (2)
- ☐ Bed and chair only (0)

Sitting
- ☐ Comfortably in ordinary chair for one hour (5)
- ☐ On a high chair for 30 minutes (3)
- ☐ Unable to sit comfortably in any chair (0)

Enter public transportation
- ☐ Yes (1)
- ☐ No (0)

Stairs
- ☐ Normally without using a railing (4)
- ☐ Normally using a railing (2)
- ☐ In any manner (1)
- ☐ Unable to do stairs (0)

Put on Shoes and Socks
- ☐ With ease (4)
- ☐ With difficulty (2)
- ☐ Unable (0)

Absence of Deformity (All yes = 4; Less than 4 =0)
- Less than 30° fixed flexion contracture ☐ Yes ☐ No
- Less than 10° fixed abduction ☐ Yes ☐ No
- Less than 10° fixed internal rotation in extension ☐ Yes ☐ No
- Limb length discrepancy less than 3.2 cm ☐ Yes ☐ No

Range of Motion (*indicates normal)
- Flexion (*140°) _____
- Abduction (*40°) _____
- Adduction (*40°) _____
- External Rotation (*40°) _____
- Internal Rotation (*40°) _____

Range of Motion Scale

211° - 300° (5)	61° - 100 (2)
161° - 210° (4)	31° - 60° (1)
101° - 160° (3)	0° - 30° (0)

Range of Motion Score _____

Total Harris Hip Score _____

Figure 4: : Harris hip score.

Following multiple splinting, for a period of 3 months, the splint was removed, but the symptoms did not subside. There was persistence of pain and the patient was unable to weight bear, do his activities of daily living on his own. Following this, he was brought for further management.

On radiographic evaluation of pelvis with both hips, the patient was diagnosed to have right hip displaced neglected neck of femur fracture nonunion (Sandhu Stage 2) (Fig. 2). The patient and attenders were explained regarding the treatment protocol and the possibility of implant back out, non-union, AVN, early arthritis, shortening, and limp.

After due anesthetic fitness, the patient underwent open reduction and internal fixation with cannulated cancellous screws. Under spinal anesthesia, the patient was positioned on a fracture table for better intraoperative imaging. Through Watson Jones approach, fracture site was reached. Fibrous tissue at the fracture edges was removed and the fragments were aligned and reduced and held initially with Kirschner wires to prevent loss of reduction. Later, the Kirschner wires were substituted by internal fixation using three 6.5 mm cannulated cancellous screws with washers under C-arm guidance.

Post-operative radiograph showed good reduction on both views (Fig. 3). Post-operative period was uneventful. The patient was started on non-weight-bearing mobilization on the 2nd post-operative day. There were no complications. Range of movement exercises of the knee was started as the patient had arthrofibrosis of the right knee due to prolonged splinting. At the end of 6 weeks, the patient was started on partial weight-bearing as tolerated and then gently on full weight-bearing. He was also started on physiotherapy in the form of hip and back strengthening exercises at the end of 6 weeks. The patient resumed his daily work and had not faced any challenges. The patient had shortening of 1.5 cm of the right lower limb but was manageable with a shoe rise and has never been a concern clinically. Functional assessment was done using Harris Hip

Figure 5: One month follow-up radiograph.

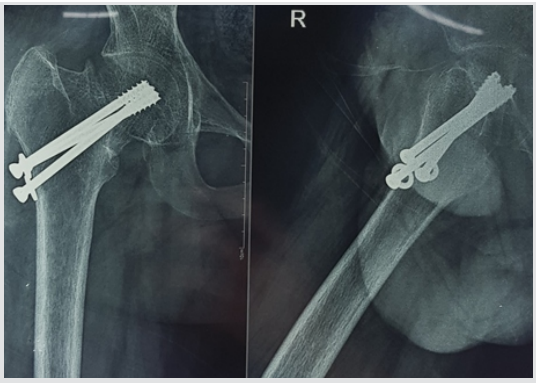

Figure 6: Six months follow-up radiographs.

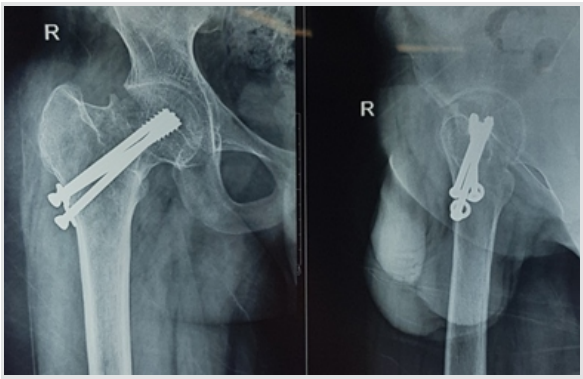

Figure 7: Ten months follow-up radiographs.

Figure 8: Clinical pictures showing good functional outcome at 15 months follow-up.

Score (Fig. 4) and was recorded at 6 weeks, 3 months, 6 months, 1 year, and 15 months follow-up. Radiologic assessment was done at the time of 1 month (Fig. 5) and until 15 months to check for fracture union and to rule out AVN of femoral head and implant loosening (Fig. 6, 7). At 15 months follow-up, Harris Hip Score was found to be 95 with excellent outcome with no restriction of movements (Fig. 8) and the fracture united completely with no evidence of AVN (Fig. 9).

S.No.	Journal	Year	Author	No of Patients	Average Age	Technique	AVN	Non Union
1	J Orthop Trauma	1990	Lifeso and Young [12]	3	51.4	Internal Fixation alone	33%	33%
2	J Orthop Trauma	1990	Lifeso and Young [12]	6	51.4	Valgus Osteotomy	17%	0
3	Indian J Orthop	2012, July	Bhuyan [12]	48	32.9	ORIF+TFL MPBG±Multiple Drilling and Cortico-Cancellous Bone Grafring	4%	6%
4	J Bone Joint Surg Br	2007, November	Gupta [12]	20	24	ORIF+QF MPBG	5%	0
5	Indian J Orthop	2009, January	Azam et al [12]	32 (28 followed)	37.8	CR/OR IF with two CCS and fibular strut graft	31%	11%
6	Clin Orthop Relat Res	2005, February	Sandhu et al [2]	168	-	CRIF+CCS+ fibular graft	3.5%	8.3%
7	Clin Orthop Relat Res	2009, April	Magu et al [12]	48	48.1	Modified Pauwels' Intertronchantric Osteotomy	4%	8%
8	J Orthop Surg (Hong Kong)	2014, April	Gupta et al [12]	60	35	Valgus Osteotomy + repositioning and fixation with DHS	6.6%	3.3%
9	Int J Low Extrem Wounds	2012, March	Kapoor et al [12]	23	-	ORIF with DHS + Valgus Osteotomy + fibular grafting	17%	0
10	Injury	2013, June	Gadegone et al [12]	41	45.41	Valgus Osteotomy + fibular strut grafting	0	5%

ORIF = Open Reduction and Internal Fixation, TFL = Tensor Fascia Lata, MPBG = Muscle Pedicle Bone Grafting, QF = Quadrus Femoris, AVN = Avascular Necrosis, CR = Closed Reduction, OR = Open Reduction, CCS = Cannulated Cancellous Screw, CRIF = Closed Reduction and Internal Fixation, DHS = Dynamic Hip Screw.

Figure 10: Various studies in association with neglected femoral neck fractures.

Figure 9: Fifteen months follow-up radiographs.

Discussion

Femoral neck fractures are rare in the adolescence in comparison to common presentation in the elderly. If presenting in adolescent age group, it is almost always due to high-energy trauma. Non-union is common after femoral neck fracture because of

- Absence of cambium layer of periosteum.
- Continuous synovial bathing.
- Vascular insufficiency.
- High velocity trauma in young adults [3].

The goals of treatment vary in elderly and young adults. In elderly patents, the treatment focuses on stable and mobile limb with weight-bearing as early as possible, usually the preferred treatment will be hip arthroplasty, whereas in young adults, the goal of treatment is to preserve the femoral head and attempt fracture union.

If the patient is brought within the golden period, within 12 h of the trauma, attempt at internal fixation using closed or open reduction gives the best outcomes. Whereas there is a whole change in the prognosis following a delayed presentation as in a neglected neck of femur fracture as the type of fracture, the anatomical site, the displacement, the comminution, and the fracture pattern, all act as variables for treating the fracture from then on and there is an increased chance of complications such as implant failure, AVN of femoral head, and non-union of the fracture. Even with such high possibilities of complications at an early post-operative period or in short-term follow-up, femoral head salvage is always indicated [4]. Definitive fixation can be accomplished with three cannulated or non-cannulated cancellous screws [5].

In this case, a school-going adolescent presented with 3 months post-traumatic neglected femoral neck fracture with non-union with supratrochanteric shortening with Type 2 Pauwels' angle and the fracture line being visible between the transcervical and basicervical region with type three Garden's classification. The widely accepted classification for neglected neck of femur is Sandhu's classification and this falls under Stage 2 [2].

Reviewing literature on treatment

The goal of treatment in neglected fracture neck of femur is to achieve a painless, mobile, and stable hip [6]. The treatment depends on the age and physical status of the patient, duration

of neglect, viability, and sphericity of the femoral head, amount of resorption of the femoral neck. Various options of management are described in the literature, all with variable outcomes in variable series [7], they are grouped as

a. Osteosynthesis with or without vascularized or non-vascularized bone grafting.

b. Osteotomy, displacement of angulation type.

c. Osteosynthesis with muscle pedicle bone grafting.

d. Replacement (hemiarthroplasty or total hip replacement).

Jain et al. [7] in his review article have included 33 articles and a total of 1336 neglected femoral neck fractures in people <50 years, who were managed by different head salvage procedures. However, no case was managed by internal fixation alone.

Roshan et al. [8] in his review article have included 22 articles and a total of 663 neglected femoral neck fractures who were managed by different procedures. Only three cases were managed by internal fixation alone. Among these three cases, two cases developed complications, one developed AVN and the other case developed non-union [9].

The outcome of neglected femoral neck fracture depends on the duration of neglect, as the changes occurring in the fracture area and fracture fragments decide the quality of biological materials required for fracture union. In Sandhu's Stage I and Stage II, osteosynthesis with open reduction and bone grafting with muscle pedicle bone grafting or valgus osteotomy achieves fracture union in almost 90% of cases. However, in Stage III, the results of osteosynthesis are poor and the treatment is replacement arthroplasty.

Fig. 10 shows a table in which various studies in association with neglected femoral neck fractures have been tabulated. The standard treatment for neglected femoral neck fractures will be internal fixation after a valgus osteotomy to convert the stress forces into compressive forces and fixation either with angle blade device or angle barrel device, thereby increasing the chance of fracture union and preventing osteonecrosis and non-union.

In our case, we had not attempted for the valgus osteotomy for two reasons:

1. Intraoperatively, we gained satisfactory reduction and length. There was only about 1 cm of shortening. As the reduction was found to be stable, we did not want to perform valgus osteotomy for a shortening of 1 cm and felt it would be detrimental.

2. Internal fixation with three cannulated cancellous screws with washers was found to be sufficient due to adequate fracture reduction and good quality of bone stock.

This experience is shared in academic purpose to impart that an isolated internal fixation alone might not suffice based on literature and the treatment plan depends on the age, time of presentation, and fracture type and following which a preposition plan need to be done to plan on valgus osteotomy if necessary and choose the right implant. However, the takeaway point is to attempt open reduction and adequate fixation and aim for fracture union even in neglected presentations of neck of femur fracture occurring in young adults with good bone stock.

Conclusion

The incidence of neglected femoral fractures is declining with improving health-care facilities in developing countries like India. It is important to achieve accurate anatomical reduction and internal fixation to reduce the incidence of complications like AVN and non-union. According to the literature, valgus osteotomy with internal fixation has given the best results and internal fixation in isolation has not provided predictable satisfactory outcomes, whereas it has to be combined with other techniques such as bone grafting and valgus osteotomy for improvement of the results. This is a rare case report on an isolated internal fixation of neglected femoral neck fracture giving a functionally good result. For osteosynthesis to succeed and remain free of osteoarthritic changes, it is essential that the head of the femur should be viable, the size of the proximal fragment to be at least 2.5 cm to provide adequate stock for the implant, and the gap between the fragments to be smaller than 2.5 cm.

Clinical Message

Always attempt to preserve the femoral head even in a neglected presentation of femoral neck fracture and aim for an open anatomical reduction and adequate internal fixation based on the quality of bone. Osteosynthesis in femoral neck fractures in young adults helps in reducing the chance of revision hip surgery following hip arthroplasties.

References

1. Meyers MH, Harvey JP Jr., Moore TM. Treatment of displaced subcapital and transcervical fractures of the femoral neck by muscle-pedicle-bone graft and internal fixation. A preliminary report on one hundred and fifty cases. J Bone Joint Surg Am 1973;55:257-74.
2. Sandhu HS, Sandhu PS, Kapoor A. Neglected fractured neck of the femur: A predictive classification and treatment by osteosynthesis. Clin Orthop Relat Res 2005;431:14-20.
3. Mohamed ME. Recent concept for management of femoral neck fracture non-union in young adults. Orthop Rheumatol 2017;6:555693.
4. Butt MF, Dhar SA, Gani NU, Farooq M, Mir MR, Halwai MA, et al. Delayed fixation of displaced femoral neck fractures in younger adults. Injury 2008;39:238-43.
5. Ly TV, Swiontkowski MF. Management of femoral neck fractures in young adults. Indian J Orthop 2008;42:3-12.
6. Kainth GS, Yuvarajan P, Maini L, Kumar V. Neglected femoral neck fractures in adults. J Orthop Surg (Hong Kong) 2011;19:13-7.
7. Jain AK, Mukunth R, Srivastava A. Treatment of neglected femoral neck fracture. Indian J Orthop 2015;49:17-27.
8. Roshan A, Ram S. The neglected femoral neck fracture in young adults: Review of a challenging problem. Clin Med Res 2008;6:33-9.
9. Lifeso R, Younge D. The neglected hip fracture. J Orthop Trauma 1990;4:287-92.

Conflict of Interest: Nil
Source of Support: Nil

Consent: The authors confirm that Informed consent of the patient is taken for publication of this case report

How to Cite this Article

Ahmed MIR, Prashanth KRT. Osteosynthesis in Neglected Femoral Neck Fracture in an Adolescent by Internal Fixation Alone – A Case Report. Journal of Orthopaedic Case Reports 2020 October;10(7): 44-48.