

# A Rare Cooccurrence of Tillaux-Chaput and Volkmann Fracture in an Adolescent Male: A Case Report

Lindy Robichaux-Edwards<sup>1</sup>, Claire Hays<sup>1</sup>, Margaret Olmedo<sup>2</sup>

## Learning Point of the Article:

Adult pattern fractures, such as a Volkmann fracture, can occur in adolescents and be surgically managed with good outcomes.

## Abstract

**Introduction:** Tillaux-Chaput fractures and Volkmann fractures rarely occur together in adolescent patients despite the common occurrence of ankle injuries in adolescent athletics. This particular injury has not previously been well documented in literature.

**Case Report:** This article describes the cooccurrence of these two fracture types in a 16-year-old male who suffered significant blunt trauma during a football game resulting in a loss of consciousness and a severe left ankle injury. History and physical examination necessitated radiographs confirming a Salter-Harris IV fracture of the left distal tibia concerning for a Tillaux-Chaput fracture. Computed tomography scans were taken to confirm the full extent of the injury. These images revealed a fracture of the left distal tibia that involved the posterior tibial metaphysis extending into the tibial plafond with no significant step-off and an avulsion fracture of the anterolateral tibial epiphysis that was laterally and anteriorly displaced.

**Conclusion:** The fracture was treated surgically with close follow-up and physical therapy. Due to the complexity of this injury, long-term follow-up is indicated to prevent fear of use after injury and monitor appropriate healing to lower the risk of post-traumatic arthritis.

**Keywords:** Tillaux fracture, Volkmann fracture, Chaput fracture, Salter-Harris IV, adolescent, case report.

## Introduction

Ankle injuries are the most common kind of injury sustained by adolescent athletes with 24.1% of those occurring in football and only 5.2% of ankle injuries being fractures with football having the highest rate of severe injuries [1,2,3]. Approximately 20% of distal tibial fractures are classified as Salter-Harris Type III, while only 1% are classified as Salter-Harris Type IV, both of which are caused by a supination-inversion type of injury [4]. A Salter-Harris IV fracture of the distal tibia will have a fracture line that traverses the metaphysis, epiphysis, and the articular surface versus the Salter-Harris Type III that spares the metaphysis [4]. The typical juvenile Tillaux fracture, a fracture which results from failure of the anterior-inferior tibiofibular ligament (AITFL) to rupture at its osseous insertion on the

inferolateral tibia causing an avulsion fracture of the anterior tibial tubercle will follow a Salter-Harris Type III fracture pattern [5,6]. During maturation, the tibial physis closes centrally first, extends medially, and finally laterally, thus allowing the lateral portion to be displaced during injury [7,8]. Involvement of the posterolateral aspect of the tibia in the adult was described by Chaput and is now termed a Tillaux-Chaput fracture [6,7]. This fracture pattern is the most common of the rotational injuries and results from a mechanism of injury, in which a supinated foot is subject to internal rotation of the leg, or more simply, external rotation of the foot [5,6]. A Volkmann fracture occurs when the posterior inferior tibiofibular ligament fails to rupture during injury resulting in a posterior malleolar fracture [9]. Our patient, a 16-year-old male football player,

Access this article online

Website:  
www.jocr.co.in

DOI:  
10.13107/jocr.2019.v09.i04.1472

## Author's Photo Gallery



Dr. Lindy Robichaux-Edwards



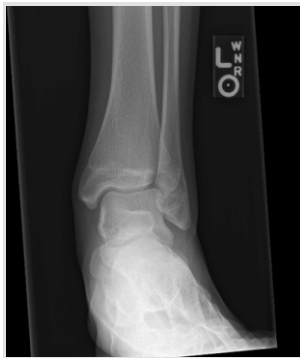Dr. Margaret Olmedo

<sup>1</sup>Department of Orthopaedics, Louisiana State University Shreveport School of Medicine, Medical Student 1501 Kings Highway, Shreveport, LA 71103, USA,  
<sup>2</sup>Associate Clinical Professor of Orthopedics, Louisiana State University Shreveport School of Medicine, University Health Shreveport, 1501 Kings Highway, Shreveport, LA 71103, USA.

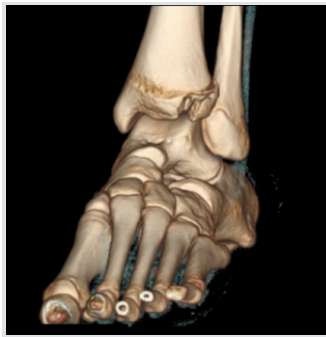## Address of Correspondence:

Dr. Margaret Olmedo,  
1501 Kings Highway, Shreveport, Louisiana 71103.  
E-mail: molmed@lsuhsc.edu

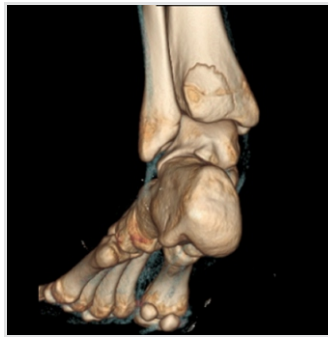



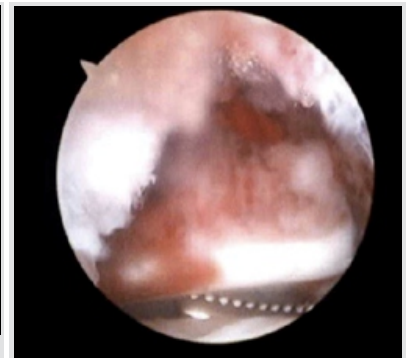
**Figure 1:** Initial left ankle X-ray, anterior-posterior view.



**Figure 2:** Left ankle three-dimensional computed tomography, anterior-posterior view showing the Tillaux-Chaput fracture.



**Figure 3:** Left ankle three-dimensional computed tomography, posterior oblique view showing Volkmann fracture.



**Figure 4:** Left ankle arthroscopic image before repair.

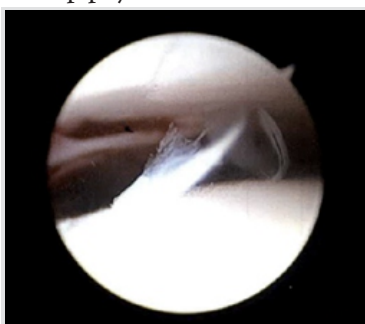
suffered a Tillaux-Chaput Salter-Harris IV fracture in combination with a Volkmann fracture warranting surgical intervention to reposition the physeal fragments appropriately[10]. Failure to accurately diagnose and appropriately treat this fracture type may result in premature degenerative arthritis and restricted ankle movements[6]. The combination of a Tillaux-Chaput and Volkmann fracture is atypical in adolescents; thus, treatment and outcomes are rarely reported.

### Case Report

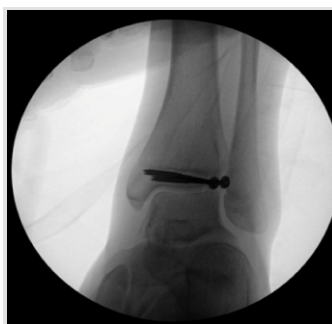Our patient is a 16-year-old male with no medical history who presented to our emergency department from another institution after being tackled in a junior varsity football game. He experienced a significant blunt trauma to the abdomen resulting in a brief loss of consciousness. He felt immediate pain in his left ankle on awakening; however, he was able to bear weight briefly until the pain became too severe. On examination, he had a generalized swelling over both the medial and lateral aspects of the left ankle compared with the right. Ecchymosis was also present on the medial side of the left ankle. He displayed tenderness to palpation over the anterolateral portion of the left ankle only. Radiographs in the anterior-posterior (Fig. 1), lateral, and oblique views revealed a Salter-Harris type IV fracture of the distal left tibia involving the posterior tibial metaphysis and the anterolateral aspect of the tibial epiphysis.

The epiphyseal fragment was displaced proximally, anteriorly, and laterally, with a 2.5 mm step-off at the articular surface seen on the lateral view. Due to high suspicion for a Tillaux fracture and inadequate evidence on plain radiographs, a computed tomography (CT) scan of the left ankle without intravenous contrast was taken. This study revealed an avulsion fracture of the anterolateral tibial epiphysis that is laterally and anteriorly displaced in addition to the non-displaced fracture of the posterior malleolus involving the metaphysis and extending into the tibial plafond with no significant step-off (Fig. 2 and 3).

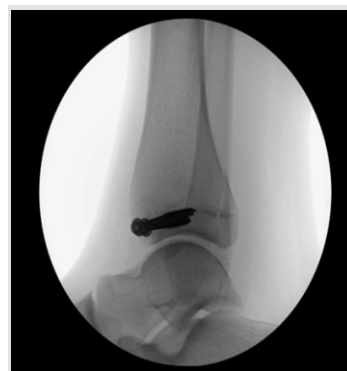The decision was made to treat surgically based on the size of the articular step-off (2.5 mm) of the epiphyseal fragment. The tibialis anterior tendon and superficial peroneal tendons were marked out on the patient's skin. An anteromedial portal for ankle arthroscopy was made and the scope was inserted. A diagnostic scope confirmed the presence of a Tillaux fracture over the anterolateral aspect of the left ankle. Soft tissue was present in the fracture site so an anterolateral portal just lateral to the superficial peroneal nerve was made and a chondrotome was inserted to debride the soft tissues. A dental pick was used to hold the fracture and reduce it under direct arthroscopic visualization. K-wires held the reduction in place while radiographs were obtained to confirm the reduction radiographically. An additional K-wire was placed to be more parallel with the joint, after which the non-parallel K-wire was removed. The K-wires were removed and measured and two 4



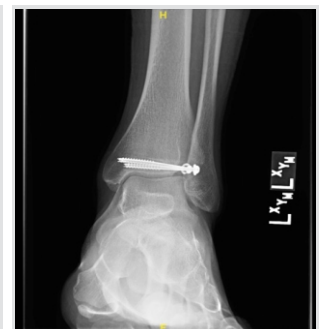**Figure 5:** Left ankle arthroscopic image showing realignment of fragments after interval placement of screw.



**Figure 6:** Anterior-posterior view of intraoperative fluoroscopic image showing interval placement of two screws.



**Figure 7:** Lateral view of intraoperative fluoroscopic image showing interval placement of two screws.



**Figure 8:** Left ankle anterior-posterior view at 1-year follow-up showing stable screws transfixing distal tibial epiphysis with congruent joint spaces and unremarkable soft tissue.

mm cannulated screws were then inserted into the distal tibia and visualized arthroscopically and radiographically (Fig. 4, 5, 6 and 7).

Final radiographs were taken and the procedure was deemed successful. The posterior malleolus fracture was also visualized on these radiographs, which was confirmed to be non-displaced. Thus, the decision was made to not use any hardware for fixation and to treat this fracture closed without fixation. The patient's left ankle was then placed in a shortleg plaster splint with instructions to remain non-weight-bearing and return to clinic in 2 weeks.

At 2 weeks postoperatively, the patient was not having any significant pain and could freely move his toes in the splint. The splint was removed and replaced with another shortleg plaster splint with continued non-weight-bearing status. Ankle strengthening and range of motion exercises were allowed to take place starting at 4 weeks postoperatively, with the patient transitioned to a controlled ankle movement (CAM) walking boot and continued non-weight-bearing status. At 8 weeks postoperatively, the patient was allowed to start balancing on his left ankle for activities of daily living and weight-shifting only, with non-weight-bearing status while walking. By 12 weeks postoperatively, the patient had weaned himself out of his CAM boot and into an aircast splint though he remained non-weight-bearing. He was tolerating weight-shifting and balancing well. At this time, the decision was made to allow him to begin weight-bearing as tolerated. At 20 weeks postoperatively, he was tolerating weight-bearing while walking and had no complaints of pain. Normal strength of the ankle joint was noted with active range of motion of 30° of plantar flexion and 20° of dorsiflexion. At 1 year postoperatively, the patient had returned to participate in athletics without restrictions and reported no pain with activity. He has retained full strength of the ankle joint and had increased his range of motion to 45° of plantar flexion and 30° of dorsiflexion. Final radiographs (Fig. 8) of the ankle show the fracture healing with no loosening of hardware.

### Discussion

The simultaneous incidence of a Tillaux-Chaput fracture with a Volkmann fracture has rarely been documented and does not often occur in adolescents. Through an extensive literature search, we found only two cases that reported the simultaneous incidence of Tillaux-Chaput and Volkmann fractures[9]. The patients in these cases were both males over the age of 30, both of whom presented following ankle sprains and were successfully treated with surgical fixation[9]. To the best of our knowledge, no similar cases have been reported in the pediatric population. The Tillaux fracture most commonly occurs in adolescents due to the physes being partially closed during the

18-month period when the distal tibial physis is undergoing fusion[11]. On forced external rotation of the foot, the AITFL ligament does not rupture as it would in adults; instead, the ligament holds and causes avulsion of the lateral tibial fragment in physes that are already partially closed[11]. Both Tillaux-Chaput fractures and Volkmann fractures may be easily missed on routine radiograph[6,12]. Anterior-posterior and lateral radiologic views of the ankle may not reveal the fracture, so oblique views are indicated if the clinician has a high index of suspicion for bony pathology despite the negative imaging[6]. A CT scan is also indicated in making the diagnosis and may be required for a complete view of the extent of the injury for appropriate treatment[8, 12,13]. Treatment for isolated Tillaux-Chaput fractures depends on the extent of the injury and the stability of the syndesmosis. Tillaux-Chaput fractures with <2mm displacement can be treated conservatively with casting and immobilization which entails a long leg cast for 4 weeks followed by short leg cast for 2 more weeks[6,8]. Fractures with displacement between 2 mm and 5 mm and articular step-off are treated operatively with large fragments and non-operatively with smaller fragments[8]. Open surgical treatment with fixation using percutaneous 4.0 mm cannulated screws or wires is one operative method[8]. The treatment of isolated Volkmann fractures similarly depends on size of the posterior malleolar fragment and will help to determine if surgical fixation is indicated, particularly when in conjunction with other ankle fractures[12]. The prognosis of an individual Tillaux fracture or Volkmann fracture is typically promising; however, when they occur in the pediatric population, they may be associated with an increased risk of osteoarthritis[10, 13]. The evenness of the articular surfaces achieved through surgical fixation plays a large part in the prevention of early-onset arthritis and joint stiffness[14]. Due to the lack of literature, long-term follow-up is indicated in our patient to ensure continued stability and satisfactory range of motion.

### Conclusion

The infrequency of this particular combination of fractures (Tillaux-Chaput, Volkmann, and Salter-Harris IV) in an adolescent and the fact that there have been very few, if any, similar cases reported, makes it difficult to ascertain a clear prognosis following surgical fixation. However, the patient responded well to surgical fixation and subsequently regained stability with the capacity to return to his athletic pursuits within 1 year of his injury, indicating a promising prognosis despite the extensiveness of his injury.

# Clinical Message

Tillaux-Chaput, Volkmann, and Salter-Harris IV fractures rarely occur simultaneously in adolescents. Thus, the methods of diagnosis, treatment, and surgical outcomes should be reported to aid other clinicians in their approach to similar injuries.

## References

1. Burns PR, Lowery N. Etiology, pathophysiology, and most common injuries of the lower extremity in the athlete. *Clin Podiatr Med Surg* 2011;28:1-8.
2. Nelson AJ, Collins CL, Yard EE, Fields SK, Comstock RD. Ankle injuries among United States high school sports athletes, 2005-2006. *J Athl Train* 2007;42:381-7.
3. Darrow CJ, Collins CL, Yard EE, Comstock RD. Epidemiology of severe injuries among United States high school athletes: 2005-2007. *Am J Sports Med* 2009;37:1798-805.
4. Podeszwa DA, Mubarak SJ. Physeal fractures of the distal tibia and fibula (Salter-harris Type I, II, III, and IV fractures). *J Pediatr Orthop* 2012;32 Suppl 1:S62-8.
5. Budny AM, Young BA. Analysis of radiographic classifications for rotational ankle fractures. *Clin Podiatr Med Surg* 2008;25:139-52, 5.
6. Sharma B, Reddy IS, Meanock C. The adult tillaux fracture: One not to miss. *BMJ Case Rep* 2013;2013:bcr2013200105.
7. Somford MP, Wiegerinck JJ, Hoornenborg D, van den Bekerom MP. Ankle fracture eponyms. *J Bone Joint Surg Am* 2013;95:e198.
8. Flynn JM, Skaggs D, Sponseller PD, Ganley TJ, Kay RM, Leitch, KK. The operative management of pediatric fractures of the lower extremity. *J Bone Joint Surg* 2002;84:2288-300.
9. Kose O, Yuksel HY, Guler F, Ege T. Isolated adult tillaux fracture associated with volkmann fracture a unique combination of injuries: Report of two cases and review of the literature. *J Foot Ankle Surg* 2016;55:1057-62.
10. Cottalorda J, Béranger V, Louahem D, Camilleri JP, Launay F, Diméglio A, et al. Salter-harris Type 3 and 4 medial malleolar fractures: Growth arrest: Is it a fate? A retrospective study of 48 cases with open reduction. *J Pediatr Orthop* 2008;28:652-5.
11. Thaunat M, Billot N, Bauer T, Hardy P. Arthroscopic treatment of a juvenile Tillaux fracture. *Knee Surg Sports Traumatol Arthrosc* 2007;15:286-8.
12. Smeeing DPJ, Houwert RM, Kruyt MC, Hietbrink F. The isolated posterior malleolar fracture and syndesmotic instability: A case report and review of the literature. *Int J Surg Case Rep* 2017;41:360-5.
13. Lu J, Holledge MM. Tillaux and Volkmann fractures: A report on two cases, treatment determined by syndesmosis instability. *Trauma Cases Rev* 2016;2:42.
14. Xu HL, Li X, Zhang DY, Fu ZG, Wang TB, Zhang PX, et al. A retrospective study of posterior malleolus fractures. *Int Orthop* 2012;36:1929-36.

**Conflict of Interest:** Nil

**Source of Support:** Nil

**Consent:** The authors confirm that Informed consent of the patient is taken for publication of this case report

## How to Cite this Article

Edwards LR, Hays C, Olmedo M. A Rare Cooccurrence of Tillaux-Chaput and Volkmann Fracture in an Adolescent Male: A Case Report. *Journal of Orthopaedic Case Reports* 2019 Jul-Aug; 9(4): 44-47.