Failure of Polyethelene Insert Locking Mechanism after a Posterior Stabilised Total Knee Arthroplasty- A Case Report

Gurava Reddy AV[1], Soundar Rajan D[1], Chiranjeevi T[1], Karthik C[1], Krishna Kiran E[2]

What to Learn from this Article?

Disengagement of polyethylene should be a differential diagnosis in patients who present with acute swelling and instability of the knee. Though it's a rare complication it is quite possible that design of the implant or its locking mechanism could contribute to dislocation.

Abstract

Introduction: Disengagement of polyethylene insert used in total knee arthroplasty is a rare but serious complication. Still rarer is disengagement because of failure of tibial insert locking mechanism. We report a previously unpublished complication of polyethylene insert locking mechanism failure in a 10-months-old posterior stabilized total knee arthroplasty in a 70-year-old woman with osteoarthritis for whom Attune (Depuy) knee implant was used.

Case Presentation: A 70-year-old female underwent (Attune,Depuy) primary bilateral posterior stabilised total knee arthroplasty in a private hospital. The patient did not have any complaints and had had been functioning well post her arthroplasty. After five months of surgery she had a fall and sustained injury over right hip which was treated with Cemented Bipolar Hemiarthroplasty. Ten months after index surgery, she sustained trivial fall and presented to the same hospital with knee pain and swelling, where the right knee prosthesis was found to be dislocated. An attempted closed reduction under anaesthesia failed, after which she was referred to our centre with an unstable, painful, swollen right knee in a long knee brace. The physical examination at the time of admission showed posterior sag of the tibia, fullness in the postero-lateral corner, quadriceps muscle atrophy without any neurovascular deficit of lower leg. Postero-lateral dislocation was confirmed with radiographs. Surgical error as a possible causative factor was excluded because patient had been functioning well after surgery. Her comorbidities included hypertension and hyponatremia. ESR and CRP were within normal limits. An open reduction surgery was planned. On exposure, polyethylene was found in the postero-lateral corner of the knee. We were not sure that revising the polyethylene alone would suffice as the poly and locking mechanism was of a relatively new design and hence it was decided to proceed with revision of the components. Revision was done with stemmed components, distal femoral augments and a constrained prosthesis (Total Condylar 3, Depuy). Intraoperative cultures were negative. The patient had an uncomplicated post-operative course.

Conclusion: Disengagement of polyethylene should be considered as a differential diagnosis in patients who present with acute swelling and instability of the knee. Though it's a rare complication, there is a possibility that design of the implant or its locking mechanism could contribute to dislocations in future.

Keywords: Total knee arthroplasty, Fixed-bearing, Disengagement of polyethylene insert, locking mechanism failure

Access this article online

Website: www.jocr.co.in

DOI: 2250-0685.492

Author's Photo Gallery


Dr. Gurava Reddy A V


Dr. SoundarRajan D


Dr. Chiranjeevi T


Dr. Karthik C


Dr. Krishna Kiran E

[1]Department of Orthopaedics, Sunshine Hospitals, Secundrabad. India.
[2]Department of Orthopaedics, Max cure Hospitals, Madhapur. India.

Address of Correspondence
Dr. Soundar Rajan D,
D, MS.Ortho., DNB., Fellow in Arthroplasty, Sunshine Hospitals, Secundrabad. India.
E-mail: soundarortho@gmail.com

Journal of Orthopaedic Case Reports | pISSN 2250-0685 | eISSN 2321-3817 | Available on www.jocr.co.in | doi:10.13107/jocr.2250-0685.492

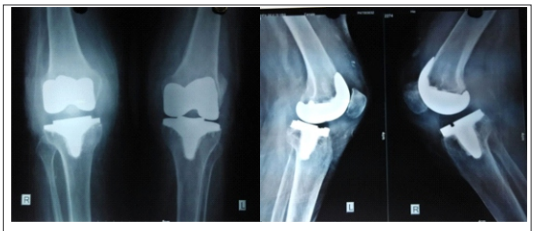

Figure 1: Immediate post op radiographs after index surgery.

Figure 2: Dislocated Right Knee prosthesis with disengagement of polyethelene.

Figure 3: Clinical picture Right knee with posterior sag.

Introduction

The disadvantage of modular total knee arthroplasty is 'backside wear' leading to periarticular osteolysis [1,12]. Tibial insert locking mechanisms are intended to limit interface motion and prevent backside wear [1, 2]. Disengagement of the locking mechanism is a rare cause of early revision and needs to be recognized [2].

The purpose of this case report is to present an unusual case of polyethylene insert locking mechanism failure after a posterior stabilised total knee arthroplasty using an Attune knee and a Vitamin E polyethylene insert (AOX), and to review literature. To our knowledge, this is the first reported case of polyethylene insert dislocation of an Attune knee.

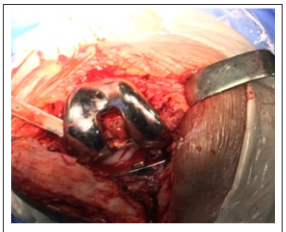

Figure 4: Dislocated polyethelene in postero-lateral corner.

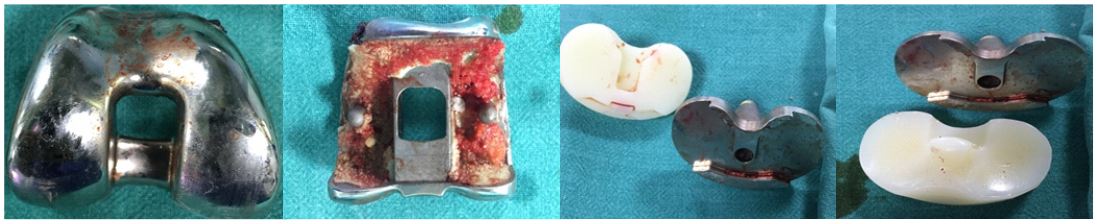

Figure 5: Retrieved components showing fatigue wear of locking mechanism in polyethylene.

Case Presentation

A 70-year-old female underwent (Attune,Depuy) primary bilateral posterior stabilised total knee arthroplasty (May '2014) for osteoarthritis in a private hospital. The femoral and tibial components were size 4 and polyethylene size was 10mm. Immediate post-operative X-ray shown in (Fig.1). She had been functioning well post her arthroplasty for five months, when she had a fall and sustained injury over right hip and was treated with Cemented Bipolar Hemiarthroplasty (Sep'2014). Ten months after index surgery, she sustained trivial fall and presented to the same hospital with knee pain and swelling, where the right knee prosthesis was found to be dislocated (Fig.2). An attempted closed reduction under anaesthesia failed, after which she was referred to our centre with an unstable, painful, swollen right knee in a long knee brace. The physical examination at the time of admission showed posterior sag of the tibia (Fig.3), fullness in the postero-lateral corner, quadriceps muscle atrophy without any neurovascular deficit of lower leg. Postero-lateral dislocation was confirmed with radiographs. Surgical error as a possible causative factor was excluded because patient had been functioning well after surgery. Her comorbidities included hypertension and hyponatremia. ESR and CRP were within normal limits.

An open reduction surgery was planned. On exposure, polyethylene was found in the postero-lateral corner of the knee (Fig.4). We were not sure that revising the polyethylene alone would suffice as the poly and locking mechanism was of a relatively new design and hence, it was decided to proceed with revision of the components. Revision was done with stemmed components, distal femoral augments and a constrained prosthesis(Fig.5) (Total Condylar 3,Depuy). Intra-operative cultures were negative. The patient had an uncomplicated post-operative course.

Discussion

The advantages of modularity of the components are to increase intraoperative flexibility, facilitate revision surgery with poly exchange and to simplify inventory management [3, 4]. Modularity in total knee arthroplasty mandated the development of locking mechanisms to capture the polyethylene into the metal base plate [5, 6].

Locking mechanism is intended to reduce interface motion and to prevent disengagement of the insert. However, rarely it may lead to failure or disengagement of locking mechanism [4, 12] resulting in dislocation of the polyethylene insert.

Disengagement of locking mechanism of the insert has been described in revision total knee arthroplsty [8, 9]. To our knowledge, disengagement of polyethylene of Attune Knee system (Attune, Depuy), which has been recently introduced, has not been reported in the literature. The design features include gradually reducing femoral radius, S-curve design of cam and spine, AOX(anti-oxidant) polyethylene and LOGICLOCKTMtibial base that has a central

Figure 6: Post-operative radiograph with stemmed ,constrained component(TC 3,Depuy).

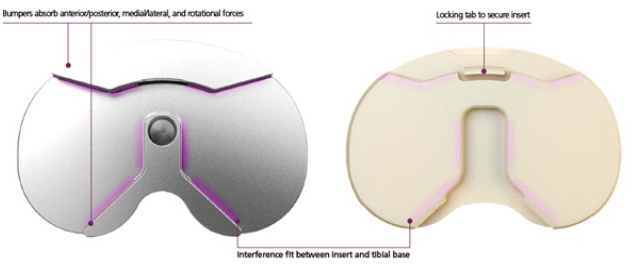

Figure 7: Locking mechanism in Attune system(DepuySynthes).

locking mechanism[7]. In our case, there was complete disengagement of the polyethylene. Retrieval analysis could not be done so it is difficult to say if the failure of locking mechanism is related to design flaw.

There are many case reports regarding screw loosening due to micro motion [2,8,10], but to the best of our knowledge disengagement of polyethylene with central locking mechanism in a newly introduced system (Attune,Depuy) as in our case has not been described.

Wright et al., postulated that repetitive flexion produced an anterior superior force leading to failure of the locking mechanism [11].

Locking mechanism failure can lead to subluxation or dissociation of the polyethylene. The mechanism are anterior lift off of the bearing in flexion resulting in an anterior displacement or posterior lift off in extension with posterior dislocation of the polyethylene [2]. In our case, there was complete dislocation of the polyethylene into the posterolateral compartment.

In our case, immediate postoperative radiographs after index surgery showed posterior slope with flexion of femoral component. Patient functioned well for 10 months after surgery, hence, surgical error at the time of index surgery can be ruled out.

There are many limitations in our case report.. We could not exactly point out the exact mechanism of locking mechanism failure and the retrieval analysis of the explanted polyethylene was not done.

Conclusion

Tibial insert locking mechanism failure is a rare but serious complication. Though it is described in revision scenario, it can occur in primary with acute knee swelling and instability. Prompt diagnosis of this issue and addressing the underlying cause is mandatory to prevent any further dislocation.

Clinical Message

Disengagement of polyethylene should be a differential diagnosis in patients who present with acute swelling and instability of the knee. Though it's a rare complication it is quite possible that design of the implant or its locking mechanism could contribute to dislocations in future.

References

1. Hepinstall MS, and Rodriguez JA. Polyethylene subluxation : A Radiographic sign of Locking Mechanism failure after Modular Total Knee Arthroplasty. The Journal of Arthroplasty 2011;26(1).
2. Emmanuel T. Failure of tibial polyethylene insert locking mechanism in posterior stabilized artroplasty. Knee Surgery, Sports Traumatology, Arthroscopy 2013;21(12):2685-2688.
3. Bhimji S, Wang A, Schmalzried T. Tibial insert micromotion of various total knee arthroplasty devices. J Knee Surg 2010;23:153-162
4. Conditt MA, Ismaily SK, AlexanderJW, Noble PC. Backside wear of modular ultra-high molecular weight polyethylene tibialinserts. J Bone Jt Surg 2004;86 :1031-1037
5. Andriacchi TP, Stanwyck TS, Galante JO.Knee biomechanics and total knee replacement. J Arthroplasty 1986;1:211-218.
6. Conditt MA, Stein JA, Noble PC.Factors affecting the severity of backside wear of modular tibialinserts.J Bone Jt Surg 2004;86:305-311.
7. Attune system brochure(DepuySynthes)
8. Chen CE, Juhn RJ, Ko JY. Dissociation of polyethylene insert from tibial baseplate following revision total knee arthroplasty. J Arthroplasty 2011;26:339-341.
9. Nadkarni JB, Carden DG. Acute locking in revision total knee due to disengagement of a locking screw. Knee Surg Sports Traumatol Arthroscop 2005;13:190-192.
10. Rapuri VR, Clarke HD, Spangehl MJ, Beauchamp CP. Five cases of failure of the tibial polyethylene insert locking mechanism in one design of constrained knee arthroplasty. J Arthroplasty 2011;26: 976.e21-e24.
11. Wright RC, Crouch A, Yacoubian SV, Raven RB 3rd, *et al.*Nontraumatic ,spontaneous dislocation of poltethylenetibial insert 1 year after TKA. Pub Med Orthopaedics 2011;34(12): 933-5.
12. Marshall A, Ries MD, Paprosky W. How prevalent are implant wear and osteolysis, and how has the scope of osteolysis changed since 2002. J Am Acad Orthop Surg 2008;16(1): S1

Conflict of Interest: Nil
Source of Support: None

How to Cite this Article

Soundar Rajan D, Gurava Reddy AV, Chiranjeevi T, Karthik C, Krishna Kiran E. FailureOf Polyethelene Insert Locking Mechanism after a Posterior Stabilised Total Knee Arthroplasty"- A Case Report. Journal of Orthopaedic Case Reports 2016 July-Aug;6(3): 35-37