

“Soap Bubble” Lesion of the Middle Phalanx: Enchondroma or Epithelioid Hemangioma

S S Suresh¹, Jamshid Etemadi¹, Gunmala Bhatnagar²

What to Learn from this Article?

Differential Diagnosis and Management of Soap Bubble Lesion of Phalanx.

Abstract

Introduction: Epithelioid hemangioma, a benign vascular tumor that arises in skin and soft tissues can also involve the skeletal system. Occasionally this has been reported from small tubular bones of the hand.

Case Report: Authors report a case of epithelioid hemangioma of the middle phalanx in a young girl without any cutaneous manifestations. The lesion presented as a swollen middle finger, and plain radiographs showed a geographic area of destruction with cortical thinning and intra lesional calcifications. The case was managed by curettage and bone grafting. Histology confirmed this as a case of epithelioid hemangioma.

Conclusion: Epithelioid hemangioma should be considered in the differential diagnosis of hand masses with expansile lytic lesions with cortical thinning.

Keywords: Hand; Vascular tumor; Enchondroma; Epithelioid hemangioma.

Introduction

Epithelioid hemangioma [EH] is a benign vascular tumor that arises in skin, soft tissue, lungs, and bone[1-3]. Skeleton is the second commonest site of involvement[3]. EH is a tumor predominantly of the long bones with lesions reported from the femur, humerus, tibia, scapula and the vertebrae[4-9]. This tumor has also been reported from small tubular bones of the hands[3]. Radiologically they present as expansile lytic area of geographic

destruction with thinning of the cortex, and definitive diagnosis is by histopathology. Immunohistochemistry for vascular markers shows CD 31 positive in cords of cells lining the blood vessels. Management is by curettage and bone grafting[5].


Case Report

16-year-old girl presented in the orthopedic clinic with a swollen right middle finger associated with occasional

Author's Photo Gallery



Dr. S S Suresh



Dr. Jamshid Etemadi



Dr. Gunmala Bhatnagar

Reviewer's Photo Gallery



Dr. Ashwani Mathur



Dr. Hemendra Agrawal

¹Department of Orthopaedics, Ibri Regional Referral Hospital, PO Box 46, Ibri 516, Sultanate of Oman.

Address of Correspondence

Dr. S S Suresh, PO Box 396, Ibri 516, Sultanate of Oman. Mobile: 00968 98822988. Email: dr.s.s.suresh@gmail.com

pain of one month duration. There was progressive increase in size. The middle phalanx was diffusely swollen, with mild tenderness. She did not have any lesions over the skin. Plain films of the right middle finger showed an expansile lesion with thinning of the cortex and intralesional calcifications.

[Fig 1]

Her complete blood count was normal. Considering her age and the radiological features a diagnosis of enchondroma was made. Computerized tomographic scan[CT scan] showed a central oval round area of geographic destruction in the medullary canal at the metaphyseal region of the middle phalanx of the right middle finger. There were dystrophic calcifications with bulbous expansion of the bone with cortical thinning. There was no soft tissue involvement. As shown in the plain films and the CT scan.

[Fig 2]

With a provisional diagnosis of enchondroma she was operated under general anesthesia. The mass was approached through a curvilinear dorsolateral approach under tourniquet. Dark- brown jelly like contents of the tumor was curetted out. There was break in the volar cortex. The defect in the bone was packed with cancellous grafts harvested from the proximal tibia.

Histopathology showed grey and dark brown tissue, with sections showing fragments of tissue composed of many perforating capillary sized blood vessels that are lined by plump endothelial cells with abundant cytoplasm and vesicular nuclei. Some cells showed vacuoles. At places there was hobnail appearance of the endothelial cells. These were admixed with numerous eosinophils, lymphocytes and few plasma cells. Occasional scattered giant cells also were seen. Immunohistochemistry for vascular markers showed CD31 positive in cords of cells and cells lining blood vessels, many CD 68 positive cells were also seen. Features were consistent with epitheloid hemangioma.

[Fig 3 & 4]

At one-year follow up, there was no recurrence of the lesion. The patient regained full movements of the finger, but the finger remained swollen.

[Fig 5 & 6].

Discussion

The differential diagnosis of expansile multi- loculated phalangeal lesions includes enchondroma, giant cell tumor of bone [GCT], aneurysmal bone cyst [ABC], and chondromyxoid fibroma[4]. Enchondromas are the most common primary tumor of the hand, presenting as expansile lesion usually of the proximal phalanx [10]. Aneurysmal cysts are occasionally reported in the phalanx, and when it occurs in the phalanx it is practically impossible to differentiate it from GCT or enchondroma[10].

In GCT of the phalanges, there is bone destruction and diaphyseal and soft tissue extension [11].

In our case because of her age and the clinical and radiological findings, a diagnosis of enchondroma was made, as enchondromas are the second commonest benign cartilaginous tumor in her age group, second only to osteochondroma[12].

In small tubular bone tumors like GCT and enchondroma there is significant amount of bone loss due to matrix resorption by osteoclasts[3]. A tumor with similar pattern in the plain films is epitheloid hemangioma[3].

Presentation of EH is pain in the involved bone; however it may be seen as an incidental finding [3]. There is equal sex predilection [13].

EH has been reported from the femur, humerus, tibia, scapula, and vertebrae, which are the usual sites [4-9]. It is a tumor predominantly of the long bones; however lesions in the small tubular bones have been reported [4]. In an analysis of 50 cases of EH, 8% of cases were with lesions of the small bones of the hand [3]. In most of the cases it presents as a solitary lesion [7].

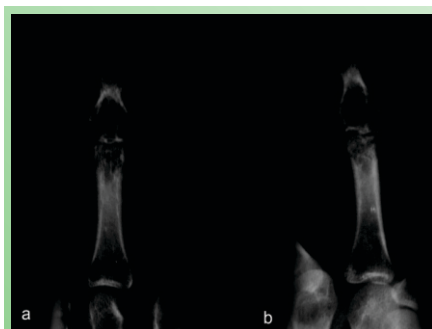


Figure 1: Plain Radiographs Showing Expansile Lesion of the Middle Phalanx with Calcifications.




Figure 2: CT Scan Showing Geographic Destruction, with Bulbous Expansion and Calcifications.

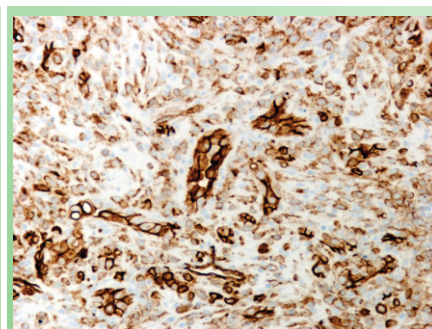


Figure 3: IHC Stain CD 31 Highlighting the Blood Vessels.

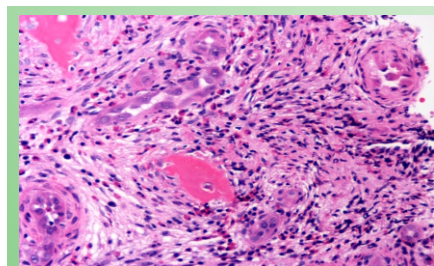


Figure 4: Hematoxylin and Eosin Stain Showing Blood Vessels Lined by Plump Epithelioid Cells and Eosinophils in the Stroma X20.

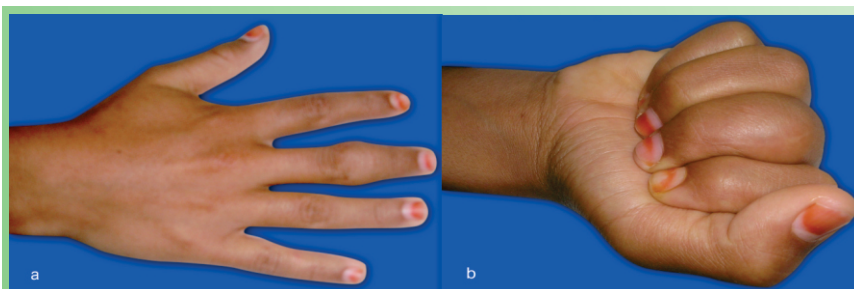


Figure 5: Clinical Photograph Showing the Range of Movements of the Finger. Figure 5 a & b Showing Range of Movements.

Lesions in the hand are expansile, with endosteal scalloping and thinning of the cortex in the meta-diaphyseal region, and rarely with matrix mineralization[12]. There may be soft tissue extension as well[3]. Endosteal scalloping was seen in 100% of cases in a report by Bierry et al; however none of their cases showed matrix mineralization[12]. There are reports of EH presenting as well defined lytic lesions of bone with sclerotic margins and intralesional calcifications[13], giving the appearance of soap bubble[2]. The expansile nature of the tumor and the cortical thinning may suggest aggressive malignancy[5]. EH is known to be associated with skin lesions, and the absence of skin lesions made us think of enchondroma as the only diagnosis[13]. Histologically there are large polyhedral cells in sheets or cords or lining numerous well defined vascular spaces. Cells are oval, with vesicular nuclei and with different sized nucleoli. There is a lobular growth pattern, with cellular lobules separated by loose connective tissue containing well formed vessels which are of capillary size[5,13].

Cytological atypia is not a feature. Vessels are surrounded by multiple epithelioid endosteal cells. The endothelial cells lining the vessels have a abundant eosinophilic cytoplasm. The sheets of epithelioid cells lining the vascular structures have “tomb stone” like arrangement [3].

Management of the lesion is by curettage and bone grafting or by marginal excision [5]. Spontaneous remission of the tumor has also been reported suggesting a benign nature of the tumor, however a case of recurrence was reported by Nielson et al.[3, 5].

Conclusion

Authors report a case of epithelioid hemangioma in a 16-year-old girl, which was clinically and radiologically diagnosed as enchondroma. Subsequent histopathological studies proved it to be a case of epithelioid hemangioma.

Clinical Message

This is a rare presentation of phalangeal tumor, and the diagnosis can be confirmed by immunohistochemistry for vascular markers.

References

1. Moran CA, Suster S. Angiolymphoid hyperplasia with eosinophilia (Epithelioid hemangioma) of the lung. *Am J Clin Pathol* 2005; 123: 762-765.
2. Cone RO, Hudkins P, Nguyen V et al. Histiocytoid hemangioma of bone: A benign lesion which may mimic angiosarcoma- report of a case and review of literature. *Skeletal Radiol* 1983; 10: 165-169.
3. Nielson GP, Srivastava A, Kattapuram S et al. Epithelioid hemangioma of bone revisited. A study of 50 cases. *Am J Surg Pathol* 2009; 33 (2): 270-277.
4. Sung MK, Kim YS, Resnick D. Epithelioid hemangioma of bone. *Skeletal Radiol* 2000; 29: 530-534.
5. Kleck CJ, Seidel MJ. Epithelioid hemangioma of the distal humerus with pathologic fracture. *Orthopedics* 2012; 35(1): e116-e119.
6. De Smet AA, Inscore D, Neff JR. Case report 521. *Skeletal Radiol* 1989; 18: 60-65.
7. Sin JM, Beck AH, Pai RK et al. Multifocal epithelioid hemangioma with reactive bone formation. *ISRN Pathology* 2011; Article ID 378940. doi: 10.5402/2011/378940. Accessed on the 29th June 2012.
8. Ose D, Vollmer R, Shelburne J et al. Histiocytoid hemangioma of the skin and scapula. A case report with electron microscopy and immunohistochemistry. *Cancer* 1983; 51(9): 1656-1662.

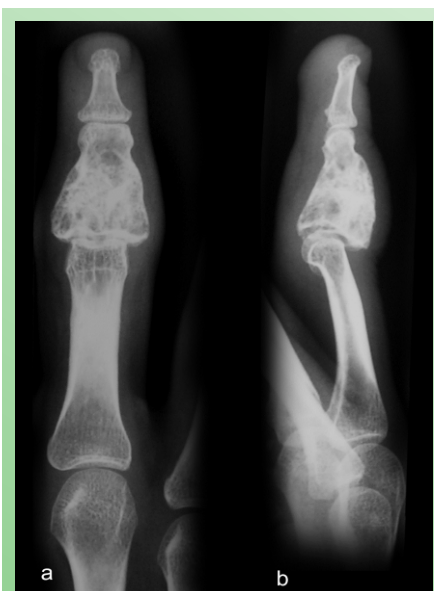

Figure 6: Radiographs Antero-posterior [a] and Lateral [b] Showing no Evidence of recurrence.

9. Sirikulchayanonta V, Jinawath A, Jaovisidha S. Epitheloid hemangioma involving three contiguous bones: a case report with a review of the literature. *Korean J Radiol* 2010; 11(6): 692-696.
10. Farzan M, Mortazavi SMJ. Osseous tumors of the hand. *Acta Medical Iranica* 2002; 40(2): 207-211.
11. Wittig JC, Simpson BM, Bickels J et al. Giant cell tumor of the hand: Superior results with curettage, cryosurgery, and cementation. *J Hand Surg* 2001; 26A: 546-555.
12. Bierry G, Kerr DA, Nielsen GP et al. Enchondromas in children: Imaging appearance with pathological correlation; *Skeletal Radiol* 2012. DOI: 10.1007/s00256-012-1377-6. Accessed on the 29th June 2012.
13. Wenger DE, Wold LE. Benign vascular lesions of bone: Radiologic and pathological features. *Skeletal Radiol* 2000; 29: 63-74.

Conflict of Interest: Nil
Source of Support: None

How to Cite this Article: Suresh SS, Etemadi J, Bhatnagar G. “Soap Bubble” Lesion of the Middle Phalanx: Enchondroma or Epitheloid Hemangioma. *Journal of Orthopaedic Case Reports* 2014 April-June;4(2): 47-50