Acute Surgical Excision of a Traumatic Fat Fracture in a Professional Soccer Player

Babar Kayani[1,2], Atif Ayuob[1,2], Elliot Onochie[1], Fares S Haddad[1,2]

Learning Point of the Article:

Acute surgical excision of a traumatic fat fracture may be used as an avenue for reducing pain, enhancing functional rehabilitation, and facilitating early return to pre-injury level of function.

Abstract

Introduction: Surgical excision of fat fractures is often reserved for patients with large chronic deformities to improve cosmetic appearance. To our knowledge, the acute surgical management of a traumatic fat fracture has not been previously reported.

Case Report: This case report describes the management of a professional soccer player that developed a traumatic fat fracture over the lateral thigh. The patient presented with persistent pain, reduced range of movement, and inability to participate in sporting activity. Symptoms were refractory to non-operative treatment. Following acute surgical excision of the fat fracture, the patient was able to make an early return to sporting activity with no complications at short-term follow-up.

Conclusion: Acute surgical excision of a traumatic fat fracture may be used as an avenue for improving pain, enhancing functional rehabilitation, and facilitating early return to pre-injury level of function.

Keywords: Acute, fat fracture, pain, trauma, surgery

Introduction

Fat fractures occur when blunt trauma leads to disruption in the architectural morphology of adipose tissue [1]. Although the term "fracture" usually describes discontinuation in the integrity of cartilage or bone, fat fractures represent a similar pathological process that leads to distortion of the organized septa within fat lobules [1, 2, 3]. Patients often present with persistent pain and localized tenderness over the affected region [1, 2, 3]. Adipose tissue over bone prominences of the gluteal region and knee joints is most commonly affected [1,3]. Initial treatment consists of conservative management with avoidance of any exacerbating factors and progressive rehabilitation, but this is associated with significant delays in returning to pre-injury level of function and high risk of recurrence with further trauma [1,2]. Surgical treatment is often reserved for patients with persistent pain or large chronic deformities to improve the cosmetic appearance of the affected region [1,4,5, 6, 7]. To our knowledge, the early surgical treatment of a traumatic fat fracture has not been previously reported. This case report describes the acute surgical excision of a fat fracture in a professional soccer player, which enabled the patient to make an early return to sporting activity without any evidence of recurrence or complications at short-term follow-up. This case report will enable patients and health-care professionals to better understand the potential role of acute surgical excision of traumatic fat fractures in enhancing rehabilitation and restoring activity in patients with high functional demands.

Case Report

A 27-year-old professional soccer goalkeeper sustained blunt trauma to his left thigh while diving to catch a football. He immediately developed pain and swelling over the lateral aspect

Access this article online

Website: www.jocr.co.in

DOI: 2250-0685.1426

Author's Photo Gallery

Dr. Babar Kayani

Dr. Atif Ayuob

Dr. Elliot Onochie

Dr. Fares S Haddad

[1]Department of Trauma and Orthopaedics, University College London Hospital, 235 Euston Road, Bloomsbury, London Nw1 2BU, United Kingdom,
[2]Department of Trauma and Orthopaedics, Princess Grace Hospital, 42-52 Nottingham Pl, Marylebone, London W1U 5NY, United Kingdom.

Address of Correspondence:
Dr. Babar Kayani,
Department of Trauma and Orthopaedics, University College London Hospital, 235 Euston Road, Bloomsbury, London NW1 2BU, United Kingdom.
E-mail: babar.kayani@gmail.com

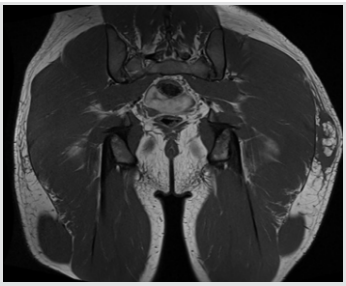

Figure 1: T1-weighted coronal magnetic resonance imaging slice showing the fat fracture in the adipose tissue between the subcutaneous tissue and fascia of the left thigh.

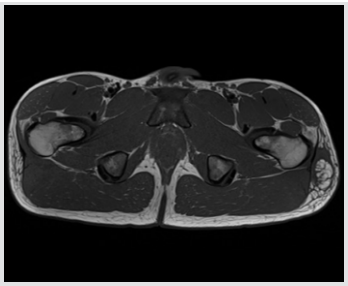

Figure 2: T1-weighted axial magnetic resonance imaging slice showing the fat fracture in the adipose tissue between the subcutaneous tissue and fascia of the left thigh.

of his left thigh below the greater trochanter. The pain was exacerbated by weight-bearing on the affected limb, radiated into the left gluteal region, and was associated with subjectively reduced range of movement in the left hip joint. He struggled with sprinting, jumping, and diving onto the affected side for the remainder of the match but managed to walk independently off the field of play after finishing the game. There was also an associated swelling over the zone of injury, which progressively increased in size in the hours following the match. The player did not have any other concurrent injuries and did not have any significant medical history. Clinical examination revealed a soft, fluctuant, lobulated mass measuring 5.0 cm × 4.0 cm approximately three finger breadths below the left greater trochanter. The mass was exquisitely tender to touch and located in the plane between the skin and underlying fascia. There was an associated effusion around the mass but no overlying erythema or breach in skin integrity. The skin was not warm to touch compared to the right side. There was no tenderness over the bony prominences of the anterior superior iliac supine, ischial tuberosity, greater trochanter, or iliac crest and no snapping of the iliotibial band over the greater trochanter. The patient had full active range of motion in the left hip and knee joints. Specialist hip tests including flexion abduction and internal rotation, flexion abduction and external rotation, Thomas test, and Ober's test were negative. The patient had a normal gait and did not require any walking aids. Plain anteroposterior and lateral radiographs of the left hip joint and left femur were unremarkable. Magnetic resonance imaging (MRI) of the left thigh revealed a well-circumscribed, lobulated mass measuring 5.2 cm × 4.3 cm × 3.2 cm in size. This was arising from the adipose tissue located between the subcutaneous tissue and fascia immediately inferior to the left greater trochanter (Figs. 1 and 2) and was associated with a surrounding effusion (Fig. 3). There was no other bone or soft-tissue pathology identified on the MRI scan. These clinical and radiological findings were consistent with an acute traumatic fat fracture. The differential diagnosis included the following: Fat fracture, benign tumor (e.g., lipoma), malignant tumor (e.g.,liposarcoma), abscess, and hematoma. The patient was reviewed by the team doctor and sports physiotherapist on the day of injury and commenced onto a supervised physiotherapy program the following day. Initial treatment consisted of resting the affected limb, avoiding any exacerbating positions or maneuvers, and limiting any pressure (e.g.,laying on the affected side, tight clothing) over the zone of injury. The patient was commenced on regular non-steroidal anti-inflammatory medication. Physiotherapy consisted of isometric muscle exercises, core strengthening, neuromuscular control activities, cryotherapy, and hydrotherapy. After 3 weeks of conservative treatment, the patient still had persistent pain and tenderness over the lateral aspect of his left thigh and could not participate in any level of training or competitive sporting activity. The patient was further counseled about the likely diagnosis and further management options. These included continuing conservative treatment, acute surgical excision, or delayed surgical excision if symptoms persisted despite further rehabilitation. As a professional soccer goalkeeper, his main treatment priorities were early return to sporting activity and minimal risk of recurrence with diving onto the affected side in the future. The patient elected to undergo acute surgical excision of the traumatic fat fracture. The procedure was performed under general anesthetic with the patient in the lateral decubitus position. A longitudinal incision measuring 6 cm center in length was centered over the soft-tissue mass, and dissection performed through the subcutaneous tissue down to the underlying capsule of the fat fracture. Finger dissection was performed between the underlying muscular fascia and the capsule of the fat fracture. Electrocautery was used to dissect fibrous bands adhering the cystic mass to the underlying fascia. The mass was excised with the surrounding capsule intact (Fig.4). Hemostasis was performed and the wound closed with absorbable sutures. Histological analysis of the excised specimen revealed lobulated and focally degenerate adipose tissue. This was covered by a thick layer of inflamed fibrous tissue which extended into the lesion. There was no evidence of fat necrosis or any neoplastic process. The findings were consistent with the working diagnosis of a fat fracture. The patient was followed up in clinic at 2 weeks after surgery. The pain over

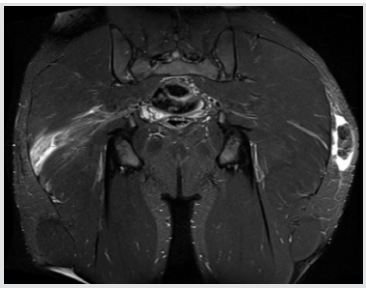

Figure 3: T2-weighted coronal magnetic resonance imaging slice showing the fat fracture with surrounding edema in the adipose tissue between the subcutaneous tissue and fascia of the left thigh.

Figure 4: Intraoperative photograph showing the excised fat fracture with surrounding capsule intact.

the left lateral thigh had completely resolved, and the patient had discontinued all analgesia. The patient had returned to his pre-injury level of sporting function without any problems. On examination, the wound was clean and wellhealed without any evidence of infection. There was no underlying collection or mass palpable, and he had full active range of motion in the left hip and knee joints. He did not require any walking aids and had a normal gait. The patient remained asymptomatic and continued to participate in full sporting activity without any complications at 1-year follow-up and was discharged from clinic at this time point.

Discussion

To our knowledge, this is the first report on the acute surgical excision of a traumatic fat fracture. The patient was a professional soccer goalkeeper that made an early return to his pre-injury level of sporting activity without any complications at short-term follow-up. Fat fractures were first described in 1972 as the "battered buttock syndrome" in a series of 12 female patients with chronic traumatic injuries leading to deformities in the gluteal region [1]. Of these, five patients were managed conservatively with improvements in pain and tenderness over the gluteal region reported at 3 months to 2 years follow-up. The remaining seven patients underwent successful surgical excision of large cosmetically deforming fat fractures causing chronic pain and/or long-standing disfigurement around the gluteal region. Individual case reports have also described ultrasound or MRI findings of fat fractures from the deltoid, quadriceps, and Achilles tendon following blunt trauma [2, 3, 5]. More recently, a case report described the surgical management of a large chronic fat fracture of the lateral thigh with surgical excision, extensive rigotomy, and fat transfer from the inner thigh [4]. The initial blunt trauma occurred 2 years before surgical excision, and the patient did not have any pain or restriction in function from the fat fracture. Surgical excision was undertaken exclusively to improve the cosmetic appearance of the thigh. The indications, timing of surgery, and surgical technique were different from those in the current study. Fat fractures arise when blunt trauma to adipose tissue leads to changes in the vascularity and/or disruptions to the architecture of fat lobules, which are conventionally arranged in tiers and supported by horizontal and vertical fibrous septa[1]. Normal physiological forces cause the lobules to flatten and dissipate the energy through the septa into the tiers. However, excessive loads may sheer these septa and disrupt these fat lobules, which creates irregularity in the layer between the epidermis and the fascia [8, 9, 10]. Fat fractures are often managed conservatively with activity modification, isometric muscle exercises, core strengthening, and neuromuscular control activities [1, 2, 3]. Symptomatic relief may also be gained by the application of topical non-steroidal anti-inflammatory agents and/or adjuvant treatment with hydrotherapy and cryotherapy[1,3,4]. Surgical intervention is often reserved for patients with chronic pain or significant cosmetic deformity. In our study, the patient received only 3 weeks of conservative treatment but made very limited progress with pain and function over this time frame. Furthermore, he was professional soccer goalkeeper and therefore delays in returning to sporting activity, and future recurrences were of significant concern to his playing career. Acute surgical intervention enabled the fat fracture to be excised and the patient to make a rapid return to his pre-injury level of function without any complications at short-term follow-up.

Conclusion

Fat fracture is an important differential diagnosis in patients with soft-tissue injury after blunt trauma. MRI facilitates diagnosis of fat fractures and aids planning of any subsequent surgical intervention. Acute surgical excision of a traumatic fat fracture may be used as an avenue for reducing pain, enhancing functional rehabilitation, and facilitating early return to pre-injury level of function.

Clinical Message

Fat fractures are rare diagnoses that may lead to persistent pain and significant impairment in physical performance. Acute surgical excision of a traumatic fat fracture should be considered as a treatment option to enhance rehabilitation and restore early functional performance.

References

1. Meggitt BF, Wilson JN. The battered buttock syndromefat fractures. A report on a group of traumatic lipomata. Br J Surg 1972;59:165-9.
2. Burkholz KJ, Roberts CC, Lidner TK. Posttraumatic pseudolipoma (Fat necrosis) mimicking atypical lipoma or liposarcoma on MRI. Radiol Case Rep 2007;2:56-60.
3. Thomas RH, Holt MD, James SH, White PG. "Fat fracture"a physical sign mimicking tendon rupture. J Bone Joint Surg Br 2001;83:204-5.
4. El Khoury J, Adams D, Saliba C, El Rayes J, Massin A, Fenoll

C, et al. Surgical approach to a post-traumatic fat fracture. Cureus 2018;10:e3378.

5. Antich TJ, Randall CC, Westbrook RA, Morrissey MC, Brewster CE. Physical therapy treatment of knee extensor mechanism disorders: Comparison of four treatment modalities*. J Orthop Sports Phys Ther 1986;8:255-9.
6. Patel RM, Soloff L, Genin J, Lund P, Schickendantz MS. Fat fracture: A rare cause of anterior and medial knee pain in a professional baseball player. Am J Orthop (Belle Mead NJ) 2018 Apr;47(4). doi: 10.12788/ajo.2018.0021.
7. Abdulla O, Beardmore S. Fat "fracture": A subcutaneous fat injury following a blunt trauma. Br J Hosp Med (Lond) 2017;78:534.
8. Theumann N, Abdelmoumene A, Wintermark M, Schnyder P, Gailloud MC, Resnick D, et al. Posttraumatic pseudolipoma: MRI appearances. Eur Radiol 2005;15:1876-80.
9. David LR, DeFranzo A, Marks M, Argenta LC. Posttraumatic pseudolipoma. J Trauma 1996;40:396-400.
10. Aust MC, Spies M, Kall S, Vogt PM. Diagnosis and treatment of posttraumatic pseudolipomas. A retrospective analysis]. Unfallchirurg 2006;109:948-55.

Conflict of Interest: Nil
Source of Support: Nil

Consent: The authors confirm that Informed consent of the patient is taken for publication of this case report

How to Cite this Article

Kayani B, Ayuob A, Onochie E, Haddad F S. Acute Surgical Excision of a Traumatic Fat Fracture in a Professional Soccer Player. Journal of Orthopaedic Case Reports 2019 May-June; 9(3): 68-71.