Case Report | Journal of Orthopaedic Case Reports 2020 December: 10(9):Page 7-10

Reconstruction of Capitellar Defect using Freeze-dried Cadaveric Allograft – A Case Report

Gurvinder Singh Kainth[1], Raghunandan Kanvinde[1]

Learning Point of the Article:

Allograft reconstruction of capitellar defect is an option of treatment for osteoporotic non-fixable capitellar fractures.

Abstract

Introduction: Elbow instability following non-reconstructible capitellum fracture could be a source of severe pain and discomfort. There are limited treatment options to address this which include either a total elbow replacement or radiocapitellar replacement. However, these can be challenging in elderly patient with low bone stock. We present such a case in a patient who was managed with reconstruction of capitellum using freeze-dried cadaveric allograft.

Case Presentation: A 64-year-old Caucasian female sustained a comminuted capitellar fracture. She was taken to theater for fixation of fracture, however, in view of severe communition, it was found to be non-reconstructible and hence had to be excised. She continued to have symptoms of pain and instability. She was treated with freeze-dried allograft from cadaveric bone to reconstruct the capitellum. Five months following surgery, she had no pain and achieved functional range of motion. At her final follow-up at 2 years, she remained asymptomatic and had full range of motion at elbow joint.

Conclusion: Capitellum reconstruction using allograft showed excellent result in short term in our patient. Ours is the first case report of using an allograft to reconstruct capitellum following severely comminuted, non-reconstructible capitellum fracture following trauma in elderly patient with osteoporotic bone.

Keywords: Trauma, capitellum fracture, instability, allograft reconstruction.

Introduction

Capitellum constitutes a part of radiocapitellar joint which is an important static stabilizer of elbow. Fractures of capitellum are typically caused by direct axial compression of elbow in semi-flexed position and these can cause potential block to motion and instability due to loss of radiocapitellar articulation. The best possible outcome is to fix the fracture fragments to restore the articular incongruity, however, in case of severely comminuted fracture with small bone stock, the fragment has to excised. In cases with persistent instability in elderly patients, the treatment options include radiocapitellar or total elbow replacement, however, these are difficult and challenging in elderly patient with poor bone stock.

Case Presentation

A 64-year-old lady presented to the emergency department following a fall and sustained isolated capitellar fracture (Fig. 1). On CT scan, this was found to be Type III capitellar fracture according to Bryan and Morrey's classification (Fig. 2). She was taken to theater on a routine trauma list and an attempt was made to fix the fracture fragment but in view of severe communition and osteoporosis, it was not possible to fix the fracture and hence the fragment was excised (Fig. 3). She was found to have mild valgus instability on table. The elbow was immobilized for few weeks in back slab and then the patient was referred to physiotherapy. She achieved range of motion of

Access this article online

Website: www.jocr.co.in

DOI: 10.13107/jocr.2020.v10.i09.1882

Author's Photo Gallery

Dr. Gurvinder Singh Kainth

Dr. Raghunandan Kanvinde

[1]Department of Trauma and Orthopaedics, Ysbyty Gwynedd, Penrhosgarnedd, Bangor, United Kingdom.

Address of Correspondence:
Dr. Gurvinder Singh Kainth,
7 Llys Adda Bangor LL57 2AW, United Kingdom.
E-mail: drgskainth@gmail.com

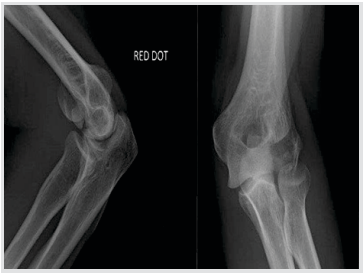

Figure 1: Radiograph of elbow showing capitellar fracture.

Figure 2: 3D reconstruction view showing capitellum fracture.

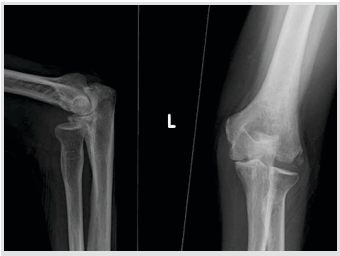

Figure 3: Lateral and anterior-posterior radiograph of elbow following capitellum excision.

Figure 4: Intraoperative picture of reconstructed capitellum using freeze-dried allograft.

30–90 degrees in elbow joint with full supination and pronation.

Her repeat radiograph at 4 months showed slight subluxation of the elbow toward radial side with some incongruency in humeroulnar joint. She continued to have pain in her elbow, especially on loading and also features of lateral instability. Radiocapitellar resurfacing option was thought of, but in view of very poor bone stock and subluxation, it was felt that this would not be suitable option for her. Other treatment options were discussed in the form of tendon interposition arthroplasty, total elbow replacement, and allograft reconstruction. All options were discussed with her and having understood the pros and cons of each procedure, she opted for capitellar reconstruction using allograft. The configuration of defect was replicated with the help of 3D printing prepared from her latest CT scans.

The freeze-dried humerus allograft was used for surgery. After GA, the patient was positioned supine on table and sterile tourniquet was used. Kocher incision was used and common extensor origin was identified and soft tissue was freed anteriorly and posteriorly to expose the lateral condyle and the size of defect was assessed. Soft tissue and synovium were removed with curette. Defect was measured with the help of ruler and guide wire and was found to be 24 mm (medial lateral) × 20 mm (height) × 16 mm depth. Similar size of capitellum and part of lateral trochlea was taken and cut precisely from allograft and care was taken not to oversize or under size it. This part of bone was placed over defect and fine-tuned with the help of burr. This was fixed with two Acutrak headless compression screws of 3.5 mm diameter (Fig. 4) and care was taken to bury the screws head under the articular surface (Fig. 5, 6). Wound was closed and the patient was immobilized in above elbow back slab for 4 weeks followed by mobilization in hinge brace for a period of 6 weeks.

Outcomes

Ten weeks following surgery, her pain score improved to 0/10 on VAS score as compared to 8/10 preoperative. Her range of motion was 20–130 degrees with full supination and pronation. Her grip and pinch strength were 12 kg and 4.1 kg, respectively, on operated side as compared to 14 kg and 4.8 kg on contralateral side. Five months following surgery, there were signs of bony union and incorporation of allograft (Fig. 7).

Her final follow-up at 2 years showed that she had no pain and had got a full range of motion with flexion extension arc of 0–140 degrees and full pronation and supination. She had Q-DASH score of 4.5. Her radiographs showed that the graft was fully incorporated (Fig. 8, 9). Although radiologically, she had signs of mild osteoarthritis of radiocapitellar joint but clinically she was asymptomatic.

Discussion

The management of elbow instability following excision of capitellum remains challenging. Our case report shows excellent results using allograft for patient presenting with elbow instability following excision of capitellum.

Persistent instability in elbow joint can cause pain and in long term leads to arthritis at the elbow joint. TEA is warranted in

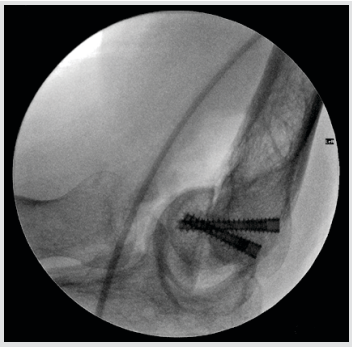

Figure 5: Lateral radiograph showing capitellum reconstruction.

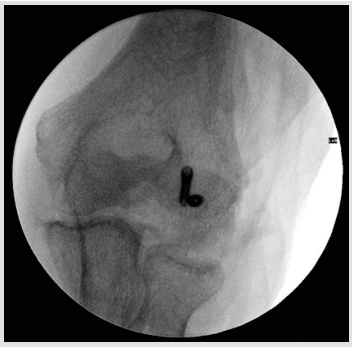

Figure 6: Anterior-posterior radiograph showing capitellum reconstruction.

Figure 7: Lateral and anterior-posterior radiograph of elbow joint 5-month post-reconstruction.

Figure 8: Anterior-posterior radiograph at final follow-up.

Figure 9: Lateral radiograph at final follow-up

such cases once all the conservative measures are exhausted. However, the 10 years survival rate of TEA following trauma is about 80–90% and patients are limited to lift weight no more than 5–10 pounds to avoid implant loosening.

Hemiarthroplasty or radiocapitellar arthroplasty is another option which could be used in such cases where there is a good bone stock and no evident subluxation on radiographs. Unfortunately, our patient did not have good bone stock for fixation of these implants. Furthermore, it is quite difficult to replicate the anatomy of native capitellum with off-shelf implants, hence, fixation of these implants leads to increased forces on the corresponding articulating parts. Sabo et al. [1] measured the contact area of spherical and hemispherical hemiarthroplasties for capitellum and found this to be 59% and 51% of the native articulation and concluded that as a result of this, radial head cartilage saw a marked increase in contact pressure relative to natural articulation. In another study [2], they concluded that the capitellum does not have a spherical surface or a circular footprint and there is substantial variability in the relationship between the height and width, and between the surface radii, that may be difficult to replicate with an off-the-shelf implant.

There has been a recent study by Giannicola et al. [3] which showed good medium-term results for radiocapitellar arthroplasty. They reported results of lateral resurfacing elbow and Uni-Elbow radiocapitellar implant and showed that their patients had Q-DASH improved by 55 points. However, these implants are relatively new and we did not have good results reported with them at the time of our surgery.

The use of allograft in elbow joint has been long known, however, this used to be for the whole elbow joint in young adults with severe bone loss. Urbaniak et al. [4] have reported their 6-year experience using cadaveric elbow allografts. Their aim was to provide patients with disabling joint symptoms who refused arthrodesis or were not candidates for total elbow replacement a useful, painless range of motion at elbow joint. They stated that the use of allograft for elbow reconstruction does not preclude subsequent reconstruction with another allograft and fusion. Thus, they concluded that in patients with deficient bone stock, the allograft reestablishes bone mass to permit an arthrodesis or reconstructive arthroplasty. Allieu et al. [5] also reported this as a salvage technique in similar group of patients and they reported the long-term clinical and radiological outcome in their series of seven patients. Their mean follow-up was 12 years (7–15 years) and the Morrey score improved in six patients. They reported that instability was proportional to the duration of graft and worsened with time.

The incorporation of allograft and union with native bone is always a concern in these patients. The study by Enneking et al. [6] demonstrated that union between the allograft and host took place slowly at cortical-cortical junction by formation of external callus derived from the cortex of the host and it took place more rapidly at cancellous-cancellous junction by internal callus advancing from the host into the allograft. They also analyzed that chondrocytes did not survive in articular cartilage even when the graft was cryoprotected before it was preserved by freezing. The necrotic cartilage functions well for as long as 5 years and as it was degenerated, it was covered by pannus of fibrovascular reparative tissue. Our case shows signs of some incorporation of graft as early as 5 months.

Nishinaka et al. [7] had reported use of costal osteochondral autografts for reconstruction of advanced stage osteochondritis dissecans of the capitellum in 22 young athletes with a mean age of 13.9 years with satisfactory results. All patients achieved rapid functional improvement and return to their former sports activity level. Although there is different pathology in our case report and his series, there is demonstration of good function at elbow following use of bone graft.

We could have used autograft from areas such as femoral condyle, but these are generally associated with morbidity of donor site and reproducing the anatomy of capitellum from these large condyles would have been a challenge. Higgins and Bürger [8] demonstrated the use of vascularized osteochondral grafts from medial and lateral femoral condyles. They used these grafts to address pathology in various areas including scaphoid, lunate, capitate, and also for capitellum. They achieved osseous healing in all capitellar defects and concluded that vascularized osteochondral flaps provide useful tool in the treatment of difficult articular problems in extremities.

Some of the patients may be reluctant to accept the allograft as it is a foreign tissue and also there is a very small risk of transmitting communicable disease, currently of 1 in million. To reduce the transmission of disease, there are guidelines for donor selection, quarantine, and tissue processing. With stringent donor selection and multistep screening, the risk of disease transmission is remote. However, it should be borne in mind that tissue banks screen a limited number of known disease and there still remains the possibility of transmission of unknown pathogens [9].

Conclusion

Allograft reconstruction of the capitellum gave excellent result in our patient in short term. The added advantage of using the allograft is that it adds to the bone stock in patients having osteoporosis or weak bone stock. To date, we have not identified any procedure using allograft for capitellar reconstruction. Our patient had evident improvement of pain score and of elbow range of motion on short term, hence keeping the possibility of performing other rescue techniques open, if they deem to be necessary in the future.

Clinical Message

Reconstruction of capitellum defect with allograft in symptomatic patients with persistent pain and instability after excision of non-fixable, comminuted capitellum fractures gives good results with restoration of bone stock.

References

1. Sabo MT, Shannon HL, Deluce S, Lalone E, Ferreira LM, Johnson JA, King GJ. Capitellar excision and hemiarthroplasty affects elbow kinematics and stability. J Shoulder Elbow Surg 2012;21:1024-31.
2. Sabo MT, McDonald CP, Ng J, Ferreira LM, Johnson JA, King GJ. A morphological analysis of the humeral capitellum with an interest in prosthesis design. J Shoulder Elbow Surg 2011;20:880-4.
3. Giannicola G, Calella P, Bigazzi P, Mantovani A, Spinello P, Cinotti G. Midterm results of radiocapitellar arthroplasty of the elbow: A multicentre prospective study on two different implants. Bone Joint J 2019;101-B:1362-9.
4. Urbaniak JR, Aitken M. Clinical use of bone allografts in the elbow. Orthop Clin North Am 1987;18:311-21.
5. Allieu Y, Marck G, Chammas M, Desbonnet P, Raynaud JP. Total elbow joint allograft for long term posttraumatic osteoarticular loss. Follow-up results at twelve years. Rev Chir Orthop Reparatrice Appar Mot 2004;90:319-28.
6. Enneking WF, Campanacci DA. Retrieved human allografts: A clinicopathological study. J Bone Joint Surg Am 2001;83:971-86.
7. Nishinaka N, Tsutsui H, Yamaguchi K, Uehara T, Nagai S, Atsumi T. Costal osteochondral autograft for reconstruction of advanced-stage osteochondritis dissecans of the capitellum. J Shoulder Elbow Surg 2014;23:1888-97.
8. Higgins JP, Bürger HK. Osteochondral flaps from the distal femur: Expanding applications, harvest sites, and indications. J Reconstr Microsurg 2014;30:483-90.
9. Delloye C, Cornu O, Druez V, Barbier O. Bone allografts: What they can offer and what they cannot. J Bone Joint Surg Br 2007;89:574-9.

Conflict of Interest: Nil
Source of Support: Nil

Consent: The authors confirm that informed consent was obtained from the patient for publication of this case report

How to Cite this Article

Kainth GS, Kanvinde R. Reconstruction of Capitellar Defect using Freeze-dried Cadaveric Allograft – A Case Report. Journal of Orthopaedic Case Reports 2020 December;10(9):7-10.