Pig Bite Injury Mimicking as Battered Baby Syndrome Leading to Bilateral Foot Amputation in a Toddler: A Diagnostic Dilemma and a Rare Case Report

Sunny Chaudhary[1], P Venkata Sudhakar[1], Sushovan Banerjee[1], Sonalika Mehta[2], Vivek Singh[1]

Learning Point of the Article:

A high index of suspicion for battered baby syndrome should be kept when a pediatric patient presents with atypical injuries , dubious history and/or delayed presentation. A multidisciplinary approach is necessary for the safety of the child.

Abstract

Introduction: Animal bites are a less common cause of pediatric injury. They are rarely associated with fractures in toddlers. Child abuse is the most closely related differential diagnosis in a child presenting with animal bite and it is a serious threat to both mental health and physical well-being of pediatric population. In all such cases with diagnostic dilemma, battered child syndrome (BCS) needs to be ruled out and reported. To the best of our knowledge, there has been no case report of bilateral femur fracture after a pig bite injury in a toddler with gangrene of bilateral foot. Hence, we report this case to highlight the importance of differentiating animal bite injuries to BCS.

Case Report: We report a rare case of pig bite injury with bilateral femur fracture and bilateral foot gangrene in a case of an 11-month-old female child suffering from BCS.

Conclusion: Apart from the medical and surgical management of pediatric injuries, it is essential to determine the cause of pediatric fractures and differentiate between abuse and accidental trauma. Identification of the etiology is significant to make sure that proper multidisciplinary intervention is initiated for the safety of the child.

Keywords: Pig bite, Femur fracture, Amputation, Battered child syndrome.

Introduction

Animal bite injuries in a child before walking age are rarely seen [1]. The presentation of animal bite injuries ranges from simple laceration over skin to grotesque limb mutilations [1]. Delay in presentation may cause infection of limb and even amputation of involved extremity [1]. However, child abuse has to be kept in mind if there is a doubtful history, delayed presentation, fracture of femur, tibia, or humerus in a child before walking age (reference).

Child abuse presents a significant threat to the social and mental upbringing of the victimized child (reference). There are different studies which have described the fractures that are considered typical of child abuse such as fractures of femur, tibia, humerus, and ribs [2, 3, 4, 5, 6]. Femur fractures femora are the most common bony injury requiring hospitalization in children and the clinician treating those injuries need to be able to recognize the etiology that has led to it [2]. There have been various attempts to recognize the different types and radiological pattern of fractures resulting from child abuse; however, these studies do not allow a clinician to confidently diagnose that the fracture sustained by the victim is the result of abuse [2].

We present a case highlighting the diagnostic dilemma of a pig bite mimicking a battered child syndrome (BCS).

Case Report

An 11-month-old female child presented to the emergency

Access this article online

Website: www.jocr.co.in

DOI: 10.13107/jocr.2020.v10.i04.1776

Author's Photo Gallery


Dr. Sunny Chaudhary


Dr. P Venkata Sudhakar


Dr. Sushovan Banerjee


Dr. Sonalika Mehta


Dr. Vivek Singh

[1]Department of Orthopedics, All India Institute of Medical Sciences, Rishikesh, Uttarakhand, India,
[2]Department of Pediatrics, All India Institute of Medical Sciences, Rishikesh, Uttarakhand, India.

Address of Correspondence:
Dr. Sunny Chaudhary,
Department of Orthopedics, All India Institute of Medical Sciences, Rishikesh - 249 203, Uttarakhand, India.
E-mail: dr.sunny.ortho@gmail.com

Figure 1: Clinical presentation. Multiple cut wounds over leg and feet.

Figure 2: Clinical presentation. Wet gangrene of foot.

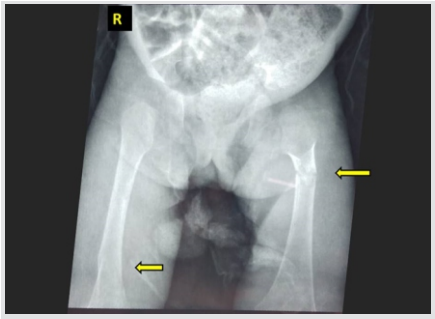

Figure 3: Anterioposterior radiograph of bilateral hips and femur. Right – distal femur fracture (AO 32-A1), Left – proximal femur fracture (AO 32-A3) – Add AO classification!.

department with injury to both lower limbs and in a state of shock. The child was not accompanied by any family member and the accompanying person gave inconclusive history. Clinical suspicion and possibility of BCS was kept in mind. The patient was stabilized in emergency department and shock was managed. The grandmother of the child presented to the emergency department after several hours and described that the injury was caused by a pig attack 2 days earlier when the child was sleeping under a tree.

Systemic examination ruled out any signs of chest or abdominal injury. On local examination, there was bilateral foot gangrene with foul smelling. There was diffuse tenderness in both thighs with multiple cut wounds over both legs and feet (Fig. 1). Wet gangrene was present over distal feet (Fig. 2). Radiographic evaluation revealed bilateral femur shaft fracture. There was a transverse fracture of the proximal femur on the left side (AO 32-A3) and a distal femur fracture on the right side (AO 32-A1) (Fig. 3). Blood counts were suggestive of neutrophilic leukocytosis along with thrombocytopenia (add specific results!). Blood cultures were sent and came out to be positive for Escherichia coli.

Primary debridement was done and a slab was applied for immobilization of limb. Midtarsal guillotine amputation was done in a second surgery 3 days after primary debridement (Fig. 4). Further management by bone drilling and vacuum-assisted closure (VAC) was done until a healthy granulation tissue was present (Fig. 5). After 10 days of VAC application, split-thickness skin grafting was done (Fig. 6). The patient was discharged in a stable condition and was advised for further follow-up in the outpatient department. The patient did not turn up for follow-up and the address given was untraceable. This further left the etiological and diagnostic puzzle unsolved and again raised suspicion of a BCS as preliminary diagnosis.

Discussion

Animal bites are more common in the rural areas. A study conducted by Sudarshan et al. in 2006 stated that dogs are the most common animals responsible for bite injuries followed by cats, monkeys, pigs, and cattle. The incidence of stray dog bites was common compared to pet dogs and it was almost equal in both urban and rural areas. In their study, pig bites were found to be more common in a rural setting [7].

In another study conducted by Gogtay et al., they also found a similar predilection with dogs being the most common animal involved in bite injuries followed by cats and pigs [8].

A wide variety of microorganisms has been reported to be isolated from domestic pig bites ranging from Staphylococcus species, streptococci, diphtheroids, Pasteurella, Mycoplasma, haemophili, bacteroids, Flavobacterium, Actinobacillus suis, amoxicillin, and clavulanate which are the recommended antibiotic treatment which covers most of the organisms isolated from domestic pig bite wounds [9].

However, often, these presenting features of animal bite wounds are accompanied with delayed presentation, atypical fractures, and suspicious history, and then, the possibility of child abuse has to kept as a differential diagnosis. In a study conducted by Baldwin et al. [10], they have proposed an algorithm to facilitate

Figure 4: Post-surgical image. Day 6 of treatment – 3 days after the guillontine amputation.

Figure 5: Post-vacuum-assisted closure dressing removal – Day 16 of treatment – 10 days after application of vacuum-assisted closure.

Figure 6: Post-surgical image. Day 21 of treatment – 5 days after split-thickness skin grafting.

the treating clinician to be able to identify the etiology of the fracture femur in younger children. In their study after doing a multiple regression analysis, they have identified three risk factors: Age <18 months, physical/radiological evidence of prior trauma in the form of healed fractures, or history suspicious of abuse. As the number of associated risk factors increases, there are high chances that the femur fracture results from child abuse.

In our study, two risk factors were present and so there was 87% chance of child abuse being the etiology. A delayed presentation and also the female gender in this region of country (relevant because XXX in this region of the country) further added up the suspicion of child abuse.

Conclusion

The diagnosis of child abuse has to be kept in mind when dealing with atypical injuries, vague history, delayed presentation, and associated fractures. A female child with injuries in Indian subcontinent escalates suspicion further. Presumptive diagnosis of child abuse for injuries associated with femur fracture should be made and these injuries require a multidisciplinary approach necessary for the safety of the child.

Clinical Message

A high index of suspicion for battered baby syndrome should be kept when a pediatric patient presents with atypical injuries, dubious history, and/or delayed presentation. A multidisciplinary approach is necessary for the safety of the child.

References

1. Vaibhav MA, Tushar SC, Venkateswara PD. Amputation in a neonate due to an animal bite. J Orthop Traumatol Rehabil 2014;7:176-8.
2. Kocher MS, Kasser JR. Orthopaedic aspects of child abuse. J Am Acad Orthop Surg 2000;8:10-20.
3. Kowal-Vern A, Paxton TP, Ros SP, Lietz H, Fitzgerald M, Gamelli RL. Fractures in the under-3-year-old age cohort. Clin Pediatr (Phila) 1992;31:653-9.
4. Arkader A, Friedman JE, Warner WC Jr., Wells L. Complete distal femoral metaphyseal fractures: A harbinger of child abuse before walking age. J Pediatr Orthop 2007;27:751-3.
5. Green M, Haggerty RJ. Physically Abused Children. Philadelphia PA: WB Saunders; 1968. p. 285-9.
6. Jones JC, Feldman KW, Bruckner JD. Child abuse in infants with proximal physeal injuries of the femur. Pediatr Emerg Care 2004;20:157-61.
7. Mysore S, Mahendra BJ, Madhusudana S, Narayana D, Rahman A, Rao N, et al. An epidemiological study of animal bites in India: Results of a WHO sponsored national multi-centric rabies survey. J Commun Dis 2006;38:32-9.
8. Gogtay NJ, Nagpal A, Mallad A, Patel K, Stimpson SJ, Belur A, et al. Demographics of animal bite victims and management practices in a tertiary care institute in Mumbai, Maharashtra, India. Indian J Med Res 2014;139:459-62.
9. Brook I. Management of human and animal bite wound infection: An overview. Curr Infect Dis Rep 2009;11:389-95.
10. Baldwin K, Pandya NK, Wolfgruber H, Drummond DS, Hosalkar HS. Femur fractures in the pediatric population: Abuse or accidental trauma? Clin Orthop Relat Res 2011;469:798-804.

Conflict of Interest: Nil
Source of Support: Nil

Consent: The authors confirm that Informed consent of the patient is taken for publication of this case report

How to Cite this Article

Chaudhary S, Sudhakar PV, Banerjee S, Mehta S, Singh V. Pig Bite Injury Mimicking as Battered Baby Syndrome Leading to Bilateral Foot Amputation in a Toddler: A Diagnostic Dilemma and a Rare Case Report. Journal of Orthopaedic Case Reports 2020 July;10(4): 5-7.