

A Rare Case of Morel-Lavallee Syndrome Complicating an Anterior Dislocation of Hip Joint

Supreeth Nekkanti¹, C Vijay¹, Sujana Theja¹, R Ravi Shankar¹, Anubhav Verma¹

What to Learn from this Article?

Morel-Lavallee Syndrome is an extremely rare complication of anterior hip dislocation and hence such patients should be closely followed up as it manifests as a late complication.

Abstract

Introduction: Hip dislocations are serious injuries as hip joint is an extremely stable joint. It requires a significant amount of force to produce such an injury. Anterior dislocations are uncommon. Potential complications of anterior hip dislocations are a neurovascular injury to femoral vessels or acetabular fractures.

Case Report: We report a rare late complication of Morel-Lavallee syndrome occurring 3 weeks after an anterior dislocation of the hip in a 43-year-old male. The patient presented to us with history.

Conclusion: Morel-Lavallee syndrome is a rare complication. However if diagnosed early can be successfully treated with minimal burden to the patient. The authors recommend surgeons to have a high index of suspicion for this syndrome and a stringent follow-up examination of the patient.

Keywords: Anterior hip dislocation, Morel-Lavallee syndrome, complication.

Introduction

Anterior dislocations of the hip joint are unusual injuries. They are relatively rare and constitute 10-15% of all dislocations [1, 2]. The strong anterior capsule and ligament of Bigelow make these injuries rare. Anterior dislocations usually lead to fractures of the anterior acetabular wall or femoral head fractures or neurovascular injuries of the femoral vessels. We report a rare case of Morel-Lavallee lesion complicating an anterior dislocation of the hip.

Case Report

A 43-year-old presented to the emergency department following a history of road traffic accident. He was apparently standing on the road when

a four-wheeler hit him from behind. The patient felt a snap following which he was unable to stand up on his affected limb. Clinical examination revealed that the limb was in external rotation and flexion. A hard mass was palpable on the anterior aspect of the groin. X-ray revealed an anterior dislocation of the hip (Fig. 1).

A closed reduction under general anesthesia was performed within 2 h of the accident. The patient was laid down in a supine position; the pelvis was fixed by an orthopedic surgeon while another orthopedic surgeon performed a continuous axial extension of the right leg till the femoral head was located distal the acetabulum, which was checked by fluoroscopy. At that moment, the hip was flexed and internal rotated. This procedure was

Author's Photo Gallery



Dr. Supreeth Nekkanti



Dr. C Vijay



Dr. Sujana Theja



Dr. R Ravi Shankar



Dr. Anubhav Verma

Access this article online

Website:
www.jocr.co.in

DOI:
2250-0685.578

¹Department of Orthopaedics, JSS Hospital, Mysore, Karnataka, India.

Address of Correspondence

Dr. Supreeth Nekkanti, No. 160, 11th Cross, 5th Main, 1st Stage, NGEF Layout, Nrupatunganagar, Nagarbhavi, Bengaluru - 560 072, Karnataka, India.
Phone: +91-9742551646.
E-mail: drsupreethn@gmail.com

Copyright © 2016 by Journal of Orthopaedic Case Reports

Journal of Orthopaedic Case Reports | pISSN 2250-0685 | eISSN 2321-3817 | Available on www.jocr.co.in | doi:10.13107/jocr.2250-0685.578

This is an Open Access article distributed under the terms of the Creative Commons Attribution Non-Commercial License (<http://creativecommons.org/licenses/by-nc/3.0/>) which permits unrestricted non-commercial use, distribution, and reproduction in any medium, provided the original work is properly cited.

followed by a snap sound. The reduction of the hip joint was confirmed with C-arm (Fig. 2).

The limb was immobilized in a Thomas splint. The patient was kept under observation for 48 h and discharged. The patient presented to us after 3 weeks with severe pain over the anteromedial aspect of thigh. There was a tense cystic swelling with ecchymosis over the medial side of thigh (Fig. 3). Ultrasonography showed multiple hypoechoic masses floating in a cystic cavity in the thigh. Aspiration using an 18 gauge needle yielded around 120 ml of blood mixed with clots (Fig. 4a and b). After aspiration, a compressive bandage was applied and antibiotics were given. The patient improved and was asymptomatic. The patient was taught pelvic bridging exercises to avoid bed sores, isometric adductor, and gluteal, and hamstring strengthening exercises initially. The patient was also encouraged ankle range of movement exercises initially. He was then made to perform quadriceps strengthening and range of movement exercises of the knee joint. After 4 weeks, at the end of 6 weeks, the patient was made to weight bear. The patient continued all his normal activities by the end of 3rd month. The patient achieved full range of movements by the end of 6 months.

Discussion

Anterior dislocations are extremely rare injuries. They constitute 10-15% of all dislocations [1, 2]. About 75% of anterior dislocations occur in males [1, 2]. Almost 35% of patients who suffer from anterior dislocations are in their third decade of life [1, 2]. On the contrary, our patient was 43-year-old and in the fourth decade of life. The ratio of anterior to posterior dislocations varies from 1:10 to 1:19 [1, 3, 4]. The rarity of these injuries is due to the strong anterior capsule and the ligament of Bigelow. Anterior dislocations are of two types, the superior iliac or pubic type and the inferior obturator type. In our patient, it was of the obturator variety of anterior dislocation.

The mechanism of injury in anterior dislocation of the hip is usually one of the three types. One is due to dashboard injury when the thigh is abducted. The second likely mode of injury is fall from a height. Finally blow to the back, when the patient is squatting seems to be a relatively more common mode of injury [1, 3, 4]. Our patient was hit from behind by a four wheeler. We suspect that the limb probably was forced into external rotation, abduction, and hyperextension at the hip joint at the time of impact.

The sequence of events that occur following trauma are the neck of the femur or the greater trochanter impinges on the rim of the acetabulum, which in turn levers out the femoral head out of the acetabulum socket. The femoral head usually pushes itself out through a tear in the anterior capsule [1, 3].

The hip joint ideally should be reduced within 6 h of fall. The incidence of avascular necrosis keeps increasing as time passes. The incidence of avascular necrosis of the femoral head in an unreduced hip after 6 h varies from 0 to 22% [1, 3]. Aware of these statistics, a successful attempt was made to reduce the hip joint within 2 h of trauma under general anesthesia.

The authors do not recommend a reduction of the hip joint under the effect of muscle relaxants, as more often than not the relaxation is not adequate to successfully reduce the joint. Moreover, excessive manipulation is

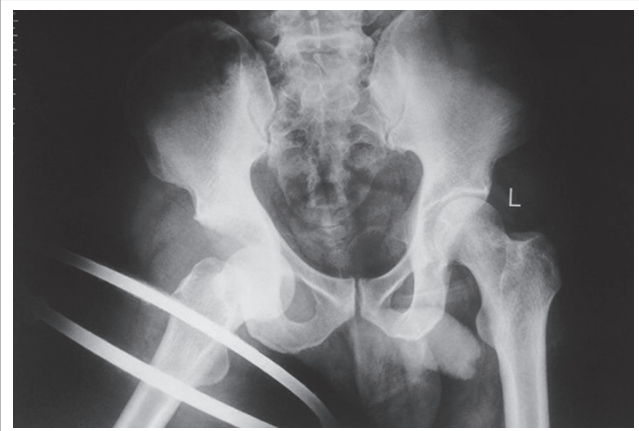


Figure 1: X-ray showing anterior dislocation of hip joint.

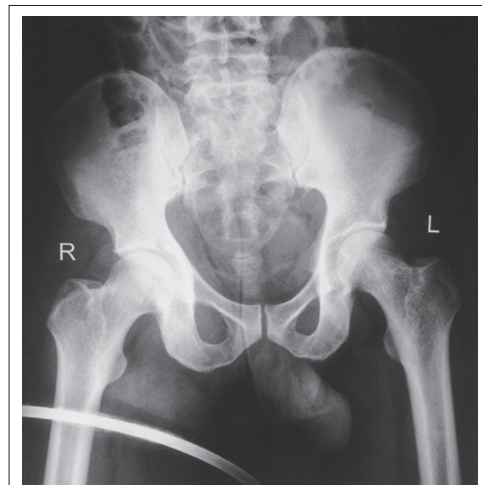


Figure 2: Check X-ray confirming reduction of hip joint.

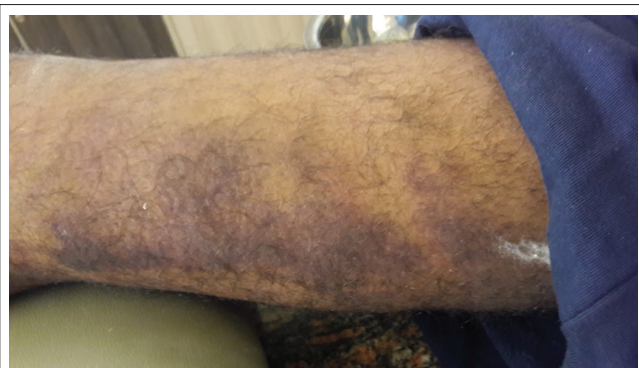

Figure 3: Clinical photo showing ecchymosis over medial aspect of thigh.

required which may lead to trauma of the retinacular or circumflex vessels. This, in turn, leads to avascular necrosis. The recommendations are to reduce the hip joint under general anesthesia.

The usual complications after an anterior dislocation of the hip include neurovascular injury of the femoral vessels [1, 5], femoral head fracture [1, 6], and acetabulum fractures [1]. Our patient did not have any of the above-mentioned complications. Our patient developed Morel-Lavallee syndrome 3 weeks after his accident. Morel-Lavallee lesion refers

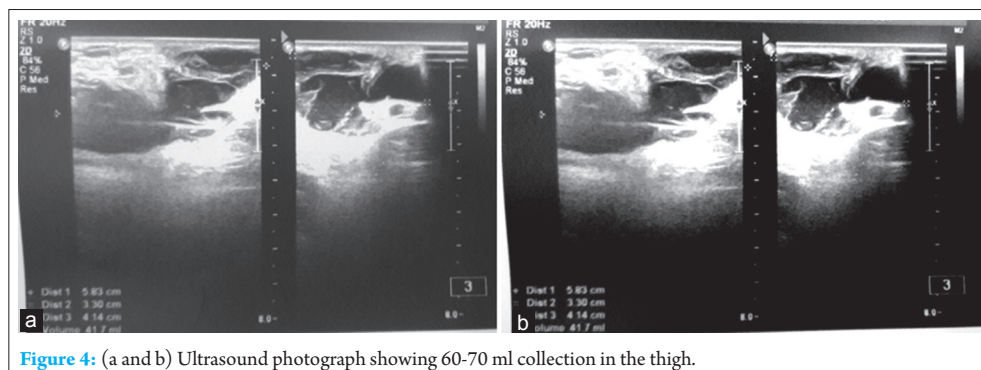


Figure 4: (a and b) Ultrasound photograph showing 60-70 ml collection in the thigh.

to a cystic lesion secondary to blunt injury and especially in degloving injuries. The mechanism behind these injuries is when a tangential shearing force acts on the relatively mobile tissue, it gets torn away from the underlying firm muscle fascia [7]. This creates a dead space between the two tissue planes which is filled with blood and/or lymph from the disrupted perforating vessels or capillaries [7, 8].

Morel-Lavelle lesions are more often encountered over the trochanteric region or the proximal thigh; however, it has been reported in other locations such as the lower lumbar region or the calf. Furthermore, they have been associated with pelvic acetabular fractures [7, 9]. In our patient, during the course of the dislocation of the femoral head anteriorly, it induces a shearing force on the subcutaneous tissues which get dragged along with it. This results in the dead space as explained above.

The key steps of the process have been identified; after the initial formation of the potential blood filled space, there is evolution of this hematoma with absorption of the blood, which is replaced by serosanguineous fluid [7, 10]. The last step in this chain of events is the formation of a peripheral fibrous capsule secondary to an anti-inflammatory reaction. The entrapment of fluid within the cyst may maintain a degree of chronic inflammation that could cause the gradual enlargement of the lesion over a long period.

In our patient, we aspirated hematoma clots from the site of injury, i.e., along the anteromedial aspect of thigh. The diagnosis was made clinically by palpating an extremely tender area on the anteromedial aspect of thigh. The diagnosis was confirmed with ultrasonography.

Most authors, however, agree that the imaging modality of choice is magnetic resonance imaging (MRI). However, the findings of an MRI may vary significantly, based on the chronicity and internal contents of the lesion. Despite the rarity of this lesion, MRI imaging has been used for the only so far available classification system [7, 11].

The available treatment modalities depend on the timing of identification of a Morel-Lavelle lesion. If it is detected during the acute phase, percutaneous drainage, and compression may be sufficient. However in later stages, surgical aspiration or excision of the fibrous capsule may be warranted [7, 12, 13]. After surgery, it would be necessary to place suction drain to drain out any remnant fluid from the cyst. The differential diagnosis of a Morel-Lavelle lesion includes posttraumatic fat necrosis, coagulopathy-related hematoma, and posttraumatic early stage myositis ossificans [7, 12].

Conclusion

In conclusion, we presented a rare case of a Morel-Lavelle lesion following anterior dislocation of the hip. Although rare, this particular entity should be looked for as it may present as a late complication such as our case. MRI is the best imaging modality for characterizing Morel-Lavelle lesions. Aspiration, compressive bandaging, and antibiotics are sufficient if diagnosed early. The results are usually good. However, surgical excision is the preferable treatment modality when the lesion is advanced.

Clinical Message

Anterior hip dislocations are rare. Atypical complications like Morel-Lavallee syndrome after hip dislocations present an unusual challenge during the treatment of the patient. Early clinical diagnosis of this condition is critical. Aid of MRI must be sought in case of doubt. Most cases respond well with almost immediate relief if diagnosed early and managed promptly. This reduces significant physical and financial burden to the patient. A diagnosis of Morel-Lavallee syndrome should be thought of as a potential late complication.

References

- Bonilla-Yoon I, Masih S, Patel DB, White EA, Levine BD, Chow K, *et al.* A rare case of open anterior hip dislocation. *J Surg Case Rep* 2013;2013(1):1-4.
- Whitehouse GH. Radiological aspects of posterior dislocation of the hip. *Clin Radiol* 1978;29(4):431-441.
- Sahni V, Karakas ES, Aksu S, Atlihan D, Turk CY, Halici M. Traumatic dislocation and fracture-dislocation of the hip: A long-term follow-up study. *J Trauma* 2003;54(3):520-529.
- Amihoud S. Anterior dislocation of the hip. *Injury* 1975;7(2):107-110.
- Schwartz DL, Haller JA Jr. Open anterior hip dislocation with femoral vessel transection in a child. *J Trauma* 1974;14(12):1054-1059.
- Jacob JR, Rao JP, Ciccarelli C. Traumatic dislocation and fracture dislocation of the hip. A long-term follow-up study. *Clin Orthop Relat Res* 1987;214:249-263.
- Kontis E, Vezakis A, Psychogiou V, Kalogeropoulos P, Polydorou

- A, Fragulidis G. Morel-lavallée lesion: Report of a case of unknown mechanism. *Case Rep Surg* 2015;2015:947450.
8. Bonilla-Yoon I, Masih S, Patel DB, White EA, Levine BD, Chow K, *et al.* The morel-lavallée lesion: Pathophysiology, clinical presentation, imaging features, and treatment options. *Emerg Radiol* 2014;21(1):35-43.
 9. Hak DJ, Olson SA, Matta JM. Diagnosis and management of closed internal degloving injuries associated with pelvic and acetabular fractures: The morel-lavallée lesion. *J Trauma* 1997;42(6):1046-1051.
 10. Li H, Zhang F, Lei G. Morel-lavallee lesion *Chin Med J (Engl)* 2014;127(7):1351-1356.
 11. Mellado JM, Bencardino JT. Morel-lavallée lesion: Review with emphasis on MR imaging. *Magn Reson Imaging Clin N Am* 2005;13(4):775-782.
 12. Nair AV, Nazar PK, Sekhar R, Ramachandran PV, Moorthy S. Morel-lavelle lesion: A closed degloving injury that requires real attention. *Indian J Radiol Imaging* 2014;24(3):288-290.
 13. Nickerson TP, Zielinski MD, Jenkins DH, Schiller HJ. The mayo clinic experience with morel-lavallée lesions: Establishment of a practice management guideline. *J Trauma Acute Care Surg* 2014;76(2):493-497.

Conflict of Interest: Nil
Source of Support: None

How to Cite this Article

Nekkanti S, Vijay C, Theja C, Shankar RR, Verma A. A Rare Case of Morel-Lavallee Syndrome Complicating an Anterior Dislocation of Hip Joint. *Journal of Orthopaedic Case Reports* 2016 Sep-Oct;6(4):73-76.