



Cysticercosis of Extensor Carpi Ulnaris – A differential diagnosis for painful swelling at elbow

Sharat Agarwal^{1*}, Mohammad Nasim Akhtar¹

ABSTRACT:

Introduction: Cysticercosis is an infection by the larval stage (*cystercus cellulosa*) of the cestode, *Taenia Solium* (pork tape worm). It occurs especially in those individuals who live in the endemic areas. After gaining entry into the body, the larva become encysted and may lie in subcutaneous tissue, striated muscle, vitreous humor, or other tissues.

Case report: We report an unusual case of cysticercosis of the Extensor carpi ulnaris (ECU) muscle, which presented as localized swelling at the lateral aspect of elbow. The diagnosis was confirmed on the musculoskeletal ultrasonographic examination of the elbow. It revealed the *Cysticercus cellulosa* as hyperechoic lesion surrounded by fluid. MRI was done later which localized the larval stage in the Extensor carpi ulnaris muscle at elbow.

Conclusion: For swelling in the region of elbow in endemic areas of tapeworm infestations, the differential diagnosis of muscle cysticercosis should be kept in mind.

Keywords: Cysticercosis; Extensor carpi ulnaris muscle; elbow region

INTRODUCTION

Cysticercus cellulosa (the larval form of *Taenia Solium*) has been found to infest the brain, musculoskeletal system, ocular muscles, and subcutaneous tissue [1-12, 15]. Here, we report an

unusual case in which an infestation by the cysticercus of the Extensor carpi ulnaris (ECU) muscle presented as a swelling with pain in the elbow region. While working on differential diagnosis in patients presenting with elbow swelling, diagnosis such as pyogenic abscess, painful neuromas, tennis elbow, rheumatoid nodules and lipomatosis are considered. Our case shows that a diagnosis of *Cysticercus cellulosa* should also be considered specially in individuals who live in endemic areas. The single cyst infection (range 47.7% to 53.4%), is most common in Indian subcontinent [13, 14]. Cysticercosis has been designated as a 'biological marker' of the social and economic development of a community. All the biological markers for transmission of *T. solium* taeniasis and cysticercosis exist in India. It is likely that the disease is under reported in India because due attention has not been given to this neglected disease and systematic population based studies are lacking. There are great disparities within the country in geography, ethnicity, religion, income, food habits, personal hygiene, level of education and standards of living, which are likely to influence the disease burden [16].

CASE PRESENTATION

We present the case of a 40 year old female patient, a housewife of good socio-economic status who attended the outpatient department (OPD) of Orthopedics & Trauma at NEIGRIHMS, Shillong with the complaint of swelling in the lateral aspect of elbow since last 6 months. Initially, the swelling was approximately the size of a pea, and it remained so for about 6 months. However last 2 weeks, it gradually increased in size and became diffused. It was associated with mild pain. On examination, the size of the swollen area was 6 x 4 cm. It had diffuse margins with a palpable pea sized firm area within this diffuse swelling. It was mildly tender with slightly increased local temperature. No cross fluctuation, transillumination or pulsations were noted. It was

¹Department of Orthopaedics and Trauma, North Eastern Indira Gandhi Regional Institute of Health and Medical Sciences (NEIGRIHMS), Shillong (Meghalaya)

*Address of Correspondance

Dr Sharat Agarwal
Department of Orthopaedics and Trauma,
North Eastern Indira Gandhi Regional Institute of Health and
Medical Sciences (NEIGRIHMS),
Shillong (Meghalaya)
Email: drsharat88@yahoo.com



attached to the underlying common extensor muscle group at the elbow and was confirmed by its movement on wrist and finger extension. The overlying skin was freely mobile with no venous prominences. The patient was a non-vegetarian and a teetotaler with no history of trauma, abnormal bowel habits, weight loss, fever, cough, urinary complaints, seizures, vomiting, loss of appetite, eye problem, xanthasma, other joint involvement or distal neurovascular deficit. Plain radiographs showed enhanced soft-tissue shadow in the lateral aspect of elbow. Musculoskeletal ultrasonographic (USG) examination of the elbow region showed hyper echoic lesion (shown by arrow Fig 1) surrounded by fluid (shown by arrow in Fig 1). Subsequently, MRI of the elbow region was done which the diagnosis of infestation of Extensor carpi ulnaris muscle by *Cysticercosis cellulosa* (Fig 2). MRI study revealed a

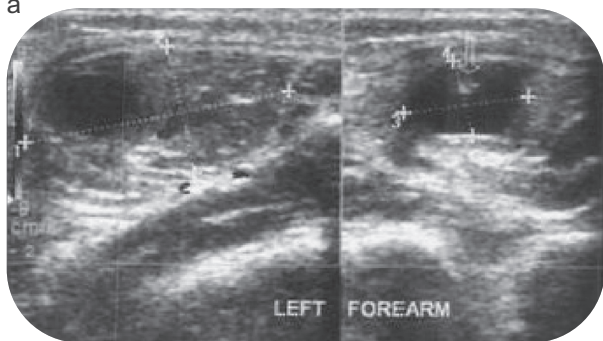


Figure 1. Musculoskeletal ultrasonographic (USG) examination of the elbow region showed the cysticercus as hyper echoic lesion (shown by arrow) surrounded by fluid

thick walled cystic lesion seen in the posterolateral aspect of left elbow joint within extensor carpi ulnaris & abutting extensor digiti minimi muscle in proximal third of left forearm (marked by arrow) associated

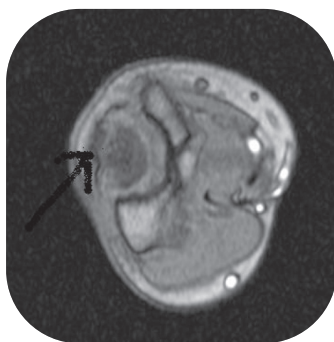


Figure 2. MRI of the elbow showing a thick walled cystic lesion seen in the posterolateral aspect of left elbow joint within extensor carpi ulnaris & abutting extensor digiti minimi muscle in proximal third of left forearm (marked by arrow).

with extensive pericystic hyperintensity in subcutaneous tissue with enhancement. The final Impression given by the radiologist was of a cystic lesion in intramuscular location (extensor carpi ulnaris) in posterolateral aspect of left elbow & with a likelihood of inflammatory granuloma (*cysticercus cellulosa*) with secondary infection.

A hemogram showed eosinophilia (17% of the WBC'S) with increased Erythrocyte Sedimentation Rate (ESR) of 30mm/1hr, without leucocytosis (Total leucocyte count-TLC: 6800/mm³). Rheumatoid factor was <5 IU, random blood sugar was 90mg% & serum uric acid levels was 3.2mg%. Stool examination was done for ova of *Taenia Solium*. However, it was found to be negative. To confirm the presence of antibodies against *Taenia Solium* in the serum, Indirect Hemagglutination test (IHA) using cysticercal antigens was advised. Eosinophilia, positive IHA test along with the USG & MRI results helped us to make the definitive diagnosis of *Cysticercosis*. Subsequently, the patient was given Albendazole (a benzimidazole derivative) at a dosage of 400 mg twice daily for a month. The swelling regressed and patient became asymptomatic after 2 months.

DISCUSSION

Swelling localized to the lateral aspect of elbow region can occur for several different reasons. The differential diagnoses include pyogenic abscess, painful neuromas, tennis elbow, rheumatoid nodules and lipomatosis to name a few. Here, we have reported an unusual case of *Cysticercosis* presenting as a swelling of the Extensor carpi ulnaris (ECU) muscle at the elbow.

Neurocysticercosis is known to occur commonly in the areas endemic for cysticercosis. Cardiac muscle cysticercosis [2,3], brown syndrome – cysticercosis involving the ocular muscles [4,5,6], *Cysticercosis* involving biceps brachii muscle [7] temporalis muscle [8], psoas muscle [9], tongue [10], flexor digitorum profundus muscle [11], tendon sheath of tendoachilles [12] & cysticercosis adjacent to the pronator teres muscle of the forearm [15] have been described. However, we could not find any report of the *Cysticercosis* of the Extensor carpi ulnaris (ECU) muscle at the elbow in the literature. It is documented that, while the larvae grow inside the cyst, they may remain minimally antigenic until the host response or chemotherapy causes gradual death of the cyst accompanied by marked inflammation and pericystic edema [17,18,19]. Radiograph of the elbow in addition to local enhancement of the soft tissue shadow may show soft tissue calcification of the

inactive cysts which may appear as oblong shaped cigar or millet lesions [20]. Stool test is insensitive for diagnosis of musculoskeletal cysticercosis and many samples may be needed over several days. However, it has been reported that about 15% of patients harbor a tapeworm at the time of diagnosis of Neurocysticercosis [21]. The test is non-specific for *T. solium* species as the eggs appear similar to those of the beef tapeworm. High resolution ultrasonography (USG) provides all information available with MRI, and more with regards to muscle pathology [22]. The diagnostic feature of a cysticercus granuloma is the presence of an oval or rounded well defined hypo echoic cystic lesion with smooth walls and an eccentric hyper echoic nidus representing the scolex within [23]. The cyst particularly the scolex may be better visualized by USG than MRI, in muscular lesions [20]. Indirect haemagglutination (IHA), Indirect fluorescent antibodies (IFA), Enzyme-linked immunosorbent assay (ELISA) and Enzyme-linked immunoelectrotransfer blot (EITB) test can be used for demonstration of specific antibodies in the serum [1]. The immune response is intense in some patients, but some show a remarkable tolerance. The serum Enzyme-linked immunoelectrotransfer blot (EITB) assay has nearly 100% specificity and 94-98% sensitivity. However, the sensitivity is only 50% if live cysts are present, and it is also low in patients with only calcified cysts. When the EITB test is not available, the older ELISA (enzyme-linked immunosorbent assay) test can be done, which has 63% specificity and 65% sensitivity with serum [1].

CONCLUSION

It seems logical to infer that the individual who presents with a swelling in the region of elbow in endemic areas of tapeworm infestations, the differential diagnosis of cysticercosis should be kept in mind. Inability to suspect & detect cysticercosis in elbow region may cause the clinician to undertake excision biopsy, which is a routine to come to a diagnosis in case of such swellings in elbow region. The aim of presenting this case is to acquaint the clinician regarding this rare presentation of cysticercosis. Although a series of investigations were done in this case, we feel that a high resolution ultrasonography (USG) with ELISA should be sufficient to reach the conclusive diagnosis and give specific medical management for this parasitic infestation in the musculoskeletal system. This may eliminate the need for surgery.

CLINICAL MESSAGE

Intramuscular Cysticercosis should be considered as a differential for pain in elbow musculature. This can be diagnosed by USG and confirmed by ELISA and requires medical management only

REFERENCES

1. Proano - Narvez JV et al: Laboratory diagnosis of Human neurocysticercosis: double blind comparison of Enzyme-linked immunosorbent assay & Electroimmunotransfer blot assay; J. Clin Microbiol. 2002; 40: 2115
2. Eberly MD, Soh EK, Bannister SP, Taraf-Motamen H, Scott JS: Isolated Cardiac Cysticercosis in an adolescent; Pediatr Infect Dis J. 2008; 27(4): 369-71.
3. Blandon R, Leandro IM: Human Cardiac cysticercosis; Rev Med Panama. 2002; 27: 37-40. Spanish.
4. Chadha V, Pandey PK, Chouhan D, Das S: Simultaneous intraocular & bilateral extra ocular muscle involvement in a case of disseminated cysticercosis; S. Int Ophthalmol. 2005 Feb-Apr; 26(1-2): 35-7.
5. Angotti -Neto H, Gonsalves AC, Moura FC, Monteiro ML: Extra ocular muscle cysticercosis mimicking Idiopathic orbital inflammation; case report; Arq Bras oftalmol Review. 2007 May-June; 70(3): 537-9.
6. Pandey PK, Bhatia A, Garg D, Singh R: Canine tooth syndrome due to superior oblique myocysticercosis; J. Pediatr Ophthalmol strabismus. 2006 May June; 43(3): 185-7.
7. Nagaray C, Singh S, Joshi A, Trikha V: Cysticercosis of biceps brachii: a rare cause of Posterior Interosseous nerve syndrome; Joint Bone Spine. 2008Mar; 75(2): 219-21.
8. Sethi PK, Sethi NK, Torgovnick J, Arsur E: Cysticercosis of Temporalis muscle: an unusual case of temporal headache; J Headache Pam 2007 Oct; 8(5): 315-6.
9. Mittal A, Sharma NS 2008 Sep : Psoas muscle cysticercosis presenting as Acute Appendicitis; J Clin Ultrasound. 2008 Sep; 36(7): 430-1.
10. Bhandary S, Sury R, Karki P, Sinha AK: Cysticercosis of Tongue-diagnostic dilemma; Pac Health Dialog. 2004 Mar; 11(1): 87-8.
11. GA Anderson, SM Chandi: Cysticercosis of the Flexor digitorum profundus muscle producing flexion deformity of the fingers; J of Hand Surgery (British & European Volume), 1993; Vol.18, No.3; 360-36.
12. Sharat Agarwal, Paragjyoti Gogoi: An unusual case of Cysticercosis of the tendon sheath of Tendoachilles – A case report; Electronic Physician. 2010; 2: 45-48.
13. Prabhakaran V, Rajshekhar V, Murell K D and Oommen A: Conformation sensitive immunoassays improve the serodiagnosis of solitary cysticercus granuloma in Indian patients; Trans. R. Soc. Trop. Med. Hyg. 2007; 101: 570-577.
14. Prasad A, Gupta R K, Nath K, Pradhan S etal: What triggers seizures in neurocysticercosis?- A MRI based study in Pig farming community from a district of North India; Parasitol. Int. 2008a; 55: 166-171.
15. Sirikulchayanonta V, Jaovisidha S: An intramuscular cysticercosis, a case report with correlation of magnetic resonance imaging and histology; J Med Assoc Thai. 2007 Jun; 90(6): 1248-52.



16. Kashi Nath Prasad, Amit Prasad, Avantika Verma and Aloukik Kumar Singh: Human cysticercosis and Indian scenario: a review; *J. Biosci.* 2008 Nov; 33(4): 571-582.
17. Kaur M, Joshi K, Ganguly NK, Mahajan RC and Malla NC: Evaluation of efficacy of Albendazole against the larvae of *Taenia solium* in experimentally infected pigs, and kinetics of immune response; *Int. J. Parasit.* 1995; 25: 1443-1450.
18. White AC, Robinson P and Khun R: *Taenia solium* cysticercosis: host parasite interaction and the immune response; *Chem. Immunol.* 1997; 66: 209-230.
19. Robinson P, Atmar RL, Lewis DE and White AC Jr.: Granuloma cytokines in murine cysticercosis; *Infect. Immun.* 1997; 65: 2925-2931.
20. Jankharia B, Chavan G, Krishnan, Jankharia B: MRI and Ultrasound in solitary muscular and soft tissue cysticercosis; *Skeletal Radiol.* 2005; 34: 722-6.
21. Gilani RH, Del Brutto OH, Garcia HH et al: Prevalence of Taeniasis among patients with neurocysticercosis is related to severity of infection. *Neurology* 2000; 55: 1062.
22. Srivastava P: *An atlas of small parts and musculoskeletal ultrasound with color flow imaging.* 3rd edition New Delhi: Jaypee Brothers Publishers; 2006.
23. Vijayaraghavan S: Sonographic appearances in cysticercosis; *J Ultrasound Med.* 2004; 23: 423-7.

Conflict of Interest : NONE

Source of Funding : NONE

Announcement from IORG

ORTHOPAEDIC LITERATURE UPDATE

Orthopaedic Literature is growing rapidly and increasing number of articles are being published in each speciality making it difficult to follow the trends in literature. Orthopaedic Literature Update is unique concept that will offer monthly review of articles published in top Journals. OLU of specialities like Arthroplasty, Arthroscopy, Paediatric Orthopaedics, Trauma, Spine and Oncology will be published monthly. These will contain a compiled review of all the articles published in particular speciality (from selected journals). This will be edited by a specialised Editorial Team and will be assessed with respect to both Evidence Based model and Practice Based models. This will not only save time for reader but will help them keep update with the literature in their respective speciality. OLU will be published online on www.orthopaedicupdate.com. All announcements will be made on the IORG website www.iorg.co.in

For any further inquiry regarding OLU mail to us at indian.ortho@gmail.com

