



Giant Cell Tumor (GCT) of Capitate

Narayana Gowda BS¹, Mohan Kumar J¹

ABSTRACT

Introduction: Giant cell tumors (GCT) of bone are not uncommon. The most common location for this tumour is distal femur, followed by proximal tibia and distal radius (the third most common location). GCT of small bone is a rare presentation. Occurrences in the hand, however, particularly in the carpal bones are rare. We report an unusual case of GCT of Capitate in a 20 year female patient.

Case presentation: A 20 year old female patient presented with history of pain in the left wrist of 6 months duration. She was diagnosed to be having GCT of Capitate which was successfully treated with curettage, phenol ablation and bone grafting. At the end of 1 year, patient was symptom free and near normal range of movements and with no evidence of recurrence.

Conclusion: Giant cell tumors usually are solitary lesions. Occurrence in the hand, particularly in the carpal bones is rare. This case report emphasizes the rarity of the lesion with only few cases reported in literature.

Keywords: Giant Cell Tumor (GCT), Lytic lesion Capitate, GCT Carpal bones

INTRODUCTION

Giant cell tumours are one of the commonest benign tumours of the bone, constituting approximately 5% of all primary bone tumours. They typically occur in patients 20 to 40 years old, and there is a slight female predominance [1-2]. Occurrence in the hand, however, particularly in the carpal bones, is rare. We report a rare case of GCT of Capitate in a 21 year old female patient.

CASE REPORT

A 20 year old female student, presented with the history of pain in the left wrist of 6 months duration. Pain increased with movements of the wrist. There was no history of trauma or pain in other joints. On examination there was fullness and tenderness present over the dorsum of the wrist with painful palmarflexion and dorsiflexion of the wrist. There was decrease in terminal 10° range of motion of the wrist joint compared to normal wrist.

Radiograph of the left wrist posteroanterior and lateral view showed a lytic lesion in the capitate bone with thinned out cortex (Fig. 1). Computed Tomography (CT scan) of the wrist revealed a non expansile lytic lesion in the left Capitate. There was no evidence of

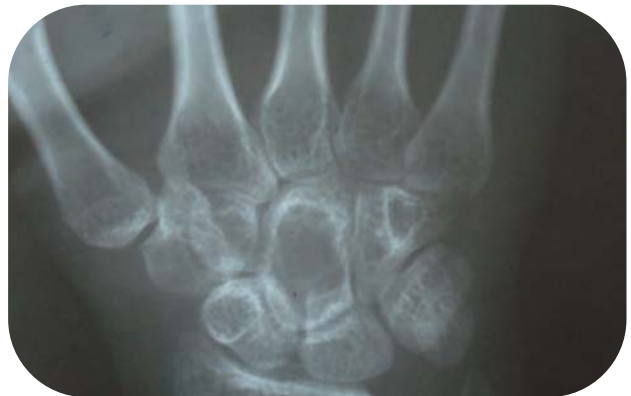

Figure 1: Plain radiograph of wrist showing lytic lesion in Capitate

¹Dept of Orthopaedics
PES Medical College, Kuppam, Chittore,
Andra Pradesh, India

Address of Correspondence

Dr. Narayana Gowda BS
Asst Professor
Dept of Orthopaedics
PES Medical College, Kuppam, Chittore,
Andra Pradesh, India
Email: drnarayan999@yahoo.com



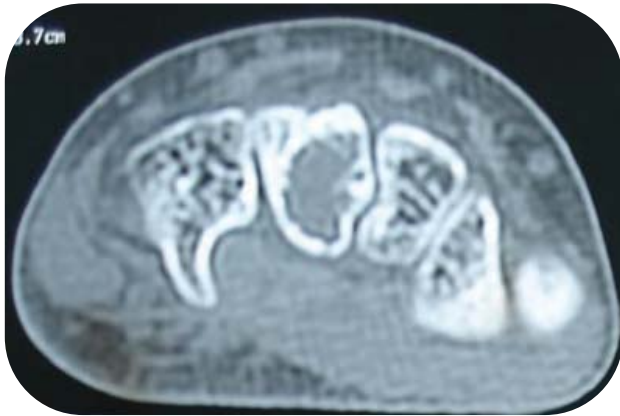

Figure 2: CT Scan wrist showing lytic lesion in Capitate

other carpal bone or joint involvement (Fig 2). Differential diagnosis at the end of imaging study included aneurismal bone cyst (ABC), giant cell tumour (GCT) and enchondroma.

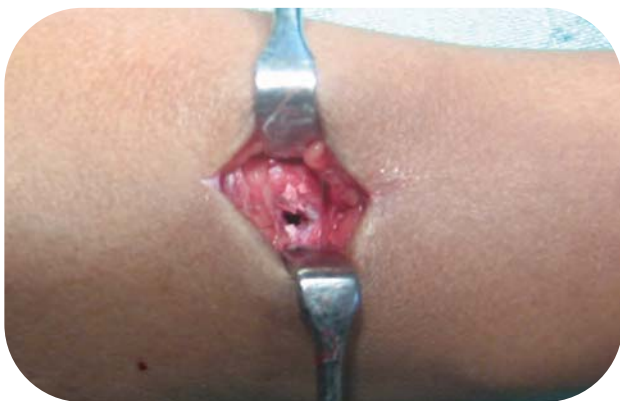

Figure 3: Intra operative picture showing cavity in Capitate after extended curettage of the lesion

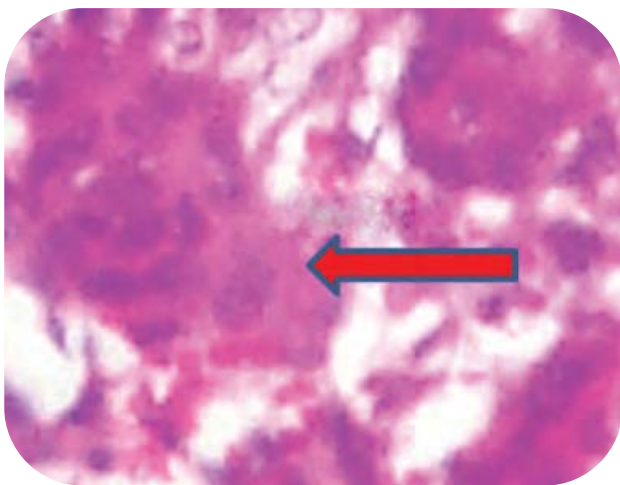


Figure 4: Histopathological photomicrograph showing multinucleated giant cell (arrow)

Patient underwent incisional biopsy of the left Capitate through a dorsal approach (Fig. 3). Histopathological examination of the specimen showed multinucleated osteoclast like giant cells and spindle cells stroma with plump nuclei consistent with the GCT (Fig. 4). One week later the lesion was curetted, followed by phenol ablation and cancellous bone grafting from the patient's iliac crest.

Patient was followed up clinically and radiologically at regular intervals of 6 weeks, 3 months, 6 months and 1 year. At the end of 1 year follow up, patient was symptom free and near normal range of movements and with no evidence of recurrence (Fig. 5).

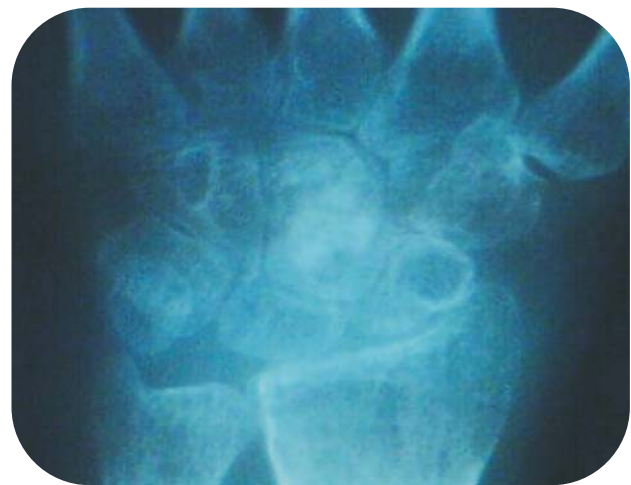

Figure 5: 1 year follow up radiograph showing no recurrence

DISCUSSION

Giant cell tumours usually are solitary lesions however, 1% to 2% may be multicentric. Occurrence in the hand, however, particularly in the carpal bones is rare, with a number of reports describing cases in the scaphoid [3], capitate [4, 5], lunate [6], hamate [7-9] and trapezium [10] Averill et al [11] reviewed 28 giant cell tumours in the hand. 26 were in the tubular bones and only two involved in the carpal bones. Howard and Lassen [12] reported a single case of giant cell tumour of the Capitate and reported finding only five additional cases of giant cell tumour of the carpal bones in the literature.

Radiographically, giant cell tumours in the carpal bones resemble other lytic lesions of bone. The radiologic differential diagnosis of solitary lesions includes aneurysmal bone cyst, enchondroma, giant cell reparative granuloma [13], brown tumour of hyperparathyroidism, post-traumatic cyst, primary malignant bone tumors such as chondrosarcomas [14], osteosarcomas and metastasis [15-17]. Of



these, brown tumour is the easiest to rule out in the absence of other changes of hyperparathyroidism. In a younger individual, metastases would also be more unusual. [6] Giant cell reparative granuloma are very similar to the solid variant of aneurysmal bone cysts and may be considered non neoplastic and reactive. These appear similar on histologically and even the treatment of curettage and bone grafting is recommended for both the entities [18-20]. Some studies have noted that GCT of hand is more frequently seen in younger individuals as in our case [21] also another difference between hand GCT and GCT in other parts of the body is its central location as oppose to eccentric location in other bones [22,23]. This is probably related to the small volume in the hand bones [24] where the lesion might begin eccentrically but by the time it is diagnosed, it is occupying a more central position in the bone.

GCT of hand skeleton is more aggressive than other locations and is mostly multifocal [15, 20]. As these are rare tumors, there is no standard protocol for treatment of these lesions. All kinds of procedures like intralesional, marginal or wide resection are reported for treatment of these lesions [5,20,22]. Uses of adjuvants like cryotherapy and phenol ablation are reported to be useful [19]. A high recurrence rates upto 87% was reported after curettage and bone grafting, however this may just indicate difficulty in complete curettage of the lesions in small bones and may not be an indicator of aggressiveness of these tumors [25]. We believe with proper curettage and use of adjuvant these lesions can be treated with minimal complication and good functional results.

CONCLUSION

GCT of the Capitate is a rare lesion, however proper diagnosis and management yields good results. Although longer follow up will be required to comment on the recurrence rates. This case report emphasizes the rarity of the lesion with only few cases reported in literature.

CLINICAL MESSAGE:

GCT of small bones like Capitate when treated with extended curettage (use of adjuvants) and bone grafting leads to good healing of the lesion.

REFERENCES

- Shigematsu K, Kobata Y, Yajima H, Kawamura K, Maegawa N, Takakura Y. Giant-cell tumors of the carpus. J Hand Surg 2006; 31(7):1214–1219
- Gupta GG, Lucas GL, Pirela-Cruz M. Multifocal giant cell tumor of the capitate, hamate, and triquetrum: a case report. J Hand Surg Am. 1995 Nov;20(6):1003-6.
- Kew J, Kumta SM, Leung PC. Case reports, giant-cell tumour in the scaphoid bone. Clin Radiol 2000;55(9): 717–778
- Howard FM, Lassen K. Giantcell tumor of the capitate. J Hand Surg [Am] 1984;9(2):272–274
- Wilson SC, Cascio BM, Plauche HR. Giant-cell tumor of the capitate. Orthopedics 2001;24(11):1085–1086
- FitzPatrick DJ, Bullough PG. Giant-cell tumor of the lunare bone: a case report. J Hand Surg [Am] 1977;2 (4):269–270
- Pintore E, Barra V, Maffulli N. Giant-cell tumor of the hamate. Case report. Scand J Plast Reconstr Hand Surg 2000;34(4):397–399
- Gould ES, Cooper JM, Potter HG, Lane LB, Cruz-Vetrano W, Bansal M, Franchi A. Case report 740: Giant cell tumor of the hamate bone. Skeletal Radiol. 1992;21(5):335-8.
- Vaccari A, Monteleone M, Boselli F, Botticelli A, Mingione A. Giant cell tumor of the hamate bone. Chir Organi Mov. 1990 Jan-Mar;75(1):77-80.
- Weiner SD, Leeson MC. Giantcell tumor of the carpal trapezium. Orthopedics 1995;18(5):482–484
- Averill RM, Smith RJ, Campbell CJ. Giant-cell tumors of the bones of the hand. J Hand Surg 1980;5A:39
- Howard FM, Lassen K. Giant cell tumor of the capitate. J Hand Surg 1984;9A:272
- Ratner V, Dorfman HD. Giant-cell reparative granuloma of the hand and foot bones. Clin Orthop Relat Res 1990;260:251–258
- Nelson DL, Abdul-Karim FW, Carter JR, Makley JT. Chondrosarcoma of the small bones of the hand arising from enchondroma. J Hand Surg Am 1990;15:655–659
- Plate AM, Steiner G, Posner MA. Malignant tumors of the hand and wrist. J Am Acad Orthop Surg 2006;14(12):680–692
- Ahlmann ER, Greene NW, Menendez LR, Stevanovic MV. Unusual locations for metastatic malignancy of the hand: a report of three cases. J Surg Orthop Adv 2008;17(4):267–270
- Athanasian EA. Malignant bone and soft-tissue sarcomas of the hand. J Am Soc Surg Hand 2004;4:60–72
- Plate AM, Lee SJ, Steiner G, Posner MA. Tumor-like lesions and benign tumors of the hand and wrist. J Am Acad Orthop Surg 2003;11(2):129–141
- Ratner V, Dorfman HD. Giant-cell reparative granuloma of the hand and foot bones. Clin Orthop Relat Res 1990;260:251–258
- Sanerkin NG, Mott MG, Roylance J. An unusual intraosseous lesion with ?broblastic, osteoclastic, osteoblastic, aneurysmal and ?bromyxoid elements: "solid" variant of aneurysmal bone cyst. Cancer 1983;51:2278–2286
- Biscaglia R, Bacchini P, Bertoni F. Giant cell tumor of the bones of the hand and foot. Cancer 2000;88(9): 2022–2032
- Szendroi M. Giant-cell tumour of bone. J Bone Joint Surg, Br 2004;86:5–12
- Levine MD, De Smet AA, Neff J. Role of radiologic imaging in management planning of giant cell tumor of the bone. Skelet Radiol 1984;12:79– 89
- Athanasian EA. Aneurysmal bone cyst and giant cell tumor of bone of the hand and distal radius. Hand Clin 2004;20 (3):269–281
- Dahlin DC, Unni KK. Bone tumors: general aspects and data on 8542 cases, 4th edn. Thomas, Springfield, 1986, pp 119-140

Conflict of Interest : NONE
Source of Funding : NONE

