

## Isolated Quadrilateral Plate Fracture of the Acetabulum – a unique case Scenario

Balaji Douraiswami<sup>1</sup>, Gauthama Vinayak<sup>1</sup>

### ABSTRACT

**Introduction:** Letournel and Judet divided acetabular fractures into elementary and associated types based on the anterior and posterior columns and walls involvement. We report the case of a patient with an isolated quadrilateral plate fracture of pelvis which does not fit in the existing classification.

**Case Description:** A young lady sustained injury to the right hip following a fall from stairs. She was diagnosed to have isolated fracture of the quadrilateral plate of the acetabulum of the right side by radiographs and CT scan, with no involvement of either columns or walls. This rare fracture was treated conservatively with good result

**Conclusion:** Our patient's case depicts a rare injury involving only the quadrilateral plate of the acetabulum with no involvement of columns or walls. This fracture pattern has not been included in the commonly followed Letournel's classification. Hence a modification of the present classification system may be suggested.

**Key words:** Quadrilateral plate, Acetabular fracture

### INTRODUCTION

Acetabular fractures are widely classified using the Judet-Letournel classification system, which divides all acetabular fractures into elementary and associated types based on the anterior and posterior columns and walls involvement [1].

<sup>1</sup>Aarupadai Veedu Medical College & Hospital,  
Kirumampakkam,  
Puducherry-607402.

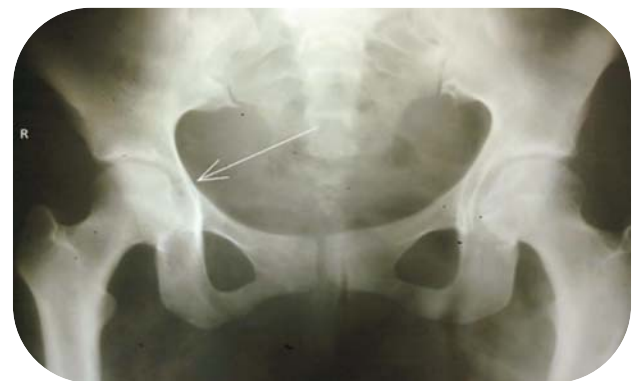**Corresponding Author:**  
Dr. Balaji Douraiswami,  
106, D. R. Nagar,  
Second cross, Kuyavarpalayam,  
Puducherry – 605013.  
Email: balaji7@jipmer.net

A young lady sustained injury to the right hip following a fall from stairs. She was diagnosed to have isolated fracture of the quadrilateral plate of the acetabulum. This is a rare type of acetabular fracture which does not fit in Letournel's classification. Only one other case similar to ours has been reported in literature [2].

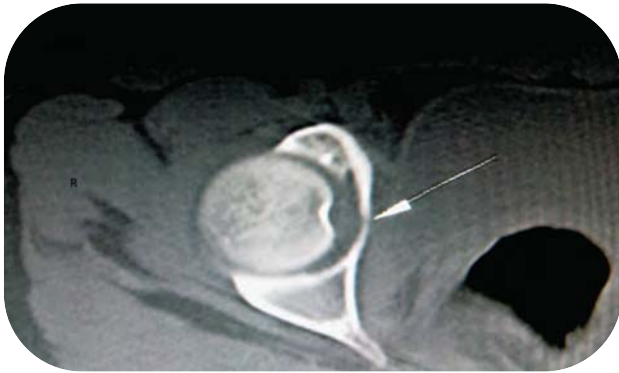Our patient's case depicts an isolated quadrilateral plate fracture of pelvis with no involvement of either column or wall, a rare injury which has not been classified so far.

### CASE REPORT

A 22 year old lady slipped from stairs and landed on the greater trochanter of her right side. On presentation to the emergency department, she had pain over her right hip and was unable to stand or walk. Her vitals were stable. Movements of her right hip were painless. Tenderness could be elicited on bi trochanteric compression. There was no distal neurovascular deficit. Radiograph was ordered. On the right side, an atypical fracture pattern could be seen on plain radiograph (Fig. 1). CT scan showed an undisplaced transverse isolated quadrilateral plate fracture of acetabulum on axial (Fig. 2) and coronal

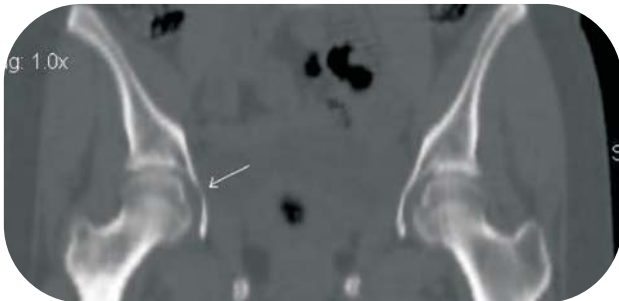


**Figure 1:** Antero posterior Radiograph of the pelvis showing acetabular fracture on the right side. (Arrow points to the fracture)



**Figure 2:** Axial CT showing undisplaced quadrilateral plate fracture on the right side. (Arrow points to the fracture)

sections (Fig. 3). There was no involvement of the acetabular walls or columns. The weight bearing portion of the acetabulum, the acetabular roof was intact (Fig. 3). We decided to treat the quadrilateral



**Figure 3:** Coronal Section showing intact acetabular roof on the right hip. (Arrow points to the fracture)

plate fracture conservatively, with non-weight bearing for 6 weeks followed by progressing weight bearing as tolerated.

**DISCUSSION**

In a recent meta-analysis, 3670 fractures of acetabulum were found to be classifiable according to Letournel's classification [3]. Fractures of quadrilateral plate are usually associated with pelvic column disruption and are classified accordingly. This particular case is unique as our patient presented only with fracture of the quadrilateral plate, with the rest of the pelvis remaining intact. Laflamme & Delislet [2] published a case of quadrilateral plate of acetabulum fracture with femoral head impaction. Meinhard and colleagues [4] published a case of an acetabular fracture with intrapelvic [central] dislocation of femoral head without major pelvic-column disruption as well as an ipsilateral femoral neck fracture. These case reports represent the final stage of severity on the same continuum on which our patient's case lies. Our patient's case depicts an isolated quadrilateral plate fracture of pelvis with no involvement of either column

or wall. Again the mechanism is more of a direct impact with femoral head directly hitting the quadrilateral plate like an anvil and thus fracturing the part bearing the impaction. Since these fractures are atypical a high index of suspicion is advised in patients presenting with direct fall on the greater tuberosity. Radiographs have to be carefully assessed to see the undisplaced fractures and a CT scan is advisable to confirm diagnosis. The hip was congruent and the weight bearing surface of acetabulum was unaffected. The quadrilateral plate is non-weight bearing and out of the roof arc [5]. Yet weight bearing may cause further progression of the fracture line, hence non weight bearing was advised for 6 weeks and further progressive weight bearing.

The present classification system does not include isolated quadrilateral plate fractures. Though uncommon, 2 cases have been reported so far (including this one), which shows that such fractures do occur with complex mechanisms of injury. There is a possibility that such fractures are under reported owing to lack of adequate description and classification under the present system. Hence a modification of the Judet–Letournel classification may be required. These fractures may be classified under the Elementary type “Transverse” as shown in Table 1. However this will require more cases to be reported and better assessment of the radiographs and CT scans in acetabulum fractures

• Posterior wall
• Posterior column
• Anterior wall
• Anterior column
• Transverse –
I. Incomplete (fracture involving the quadrilateral plate alone)
ii. Complete (fracture separating the innominate bone into two fragments)

**Table 1.** Elementary Classes in Letournel – Judet Classification with suggested modification (Transverse I)

**CONCLUSION**

Our case report depicts a rare injury involving only the quadrilateral plate of the acetabulum with no involvement of columns or walls. This fracture pattern has not been included in the commonly followed Letournel's classification. Hence a slight modification of the present classification system may be considered including such fractures in the Elementary



type as Incomplete Transverse.

**CLINICAL MESSAGE**

*Fractures of the Acetabulum are caused by complex mechanisms of trauma. Isolated quadrilateral plate fracture of the acetabulum may represent the initial stage of severity on the same continuum on which the rest of the fracture patterns classified earlier occur. Consequently a modification of the present classification system including this fracture is required.*

**Editors Note: We urge our readers to please be diligent and report any other case of Isolated Quadrilateral plate fractures. We will be pleased to receive an opinion on this case report as a letter to Editor or as a commentary which if accepted will be published in the next issue of the Journal.**

**REFERENCES**

1. Judet R, Judet J, Letournel E. Fractures of the acetabulum.

Classification and surgical approaches for open reduction. J Bone Joint Surg Am 1964;46:1615-46.

2. G. Yves Laflamme, Josee Delisle, Stephane Leduc, Pierre-Andre Uzel. Isolated quadrilateral plate fracture: an unusual acetabular fracture. Can J Surg 2009;52:E217-9.

3. Giannoudis PV, Grotz MRW, Papakostidis, et al. Operative treatment of displaced fractures of the acetabulum. A meta-analysis. J Bone Joint Surg Br 2005;87:2-9.

4. Meinhard BP, Misoul C, Joy D, et al. Central acetabular fracture with ipsilateral femoral-neck fracture and intrapelvic dislocation of the femoral head without major pelvic-column disruption. J Bone Joint Surg Am 1987;69:612-5

5. Matta JM. Fractures of the acetabulum: accuracy of reduction and clinical results in patients managed operatively within three weeks after the injury. J Bone Joint Surg Am 1996;78:1632-45.

Conflict of Interest : NONE

Source of Funding : NONE

## Requirement and steps for applying for Indian Orthopaedic Research Group Associate Membership

The applicant has to be an orthopaedic surgeon or has to be a trainee enrolled into orthopaedic training programme. Certificate of passing/degree certificate or Certificate of Enrolment into the course are a prerequisite and have to be submitted with a completely filled application form as attached at the end of this page.

The applicant will be required to pay a membership fees of 1000 INR (30 USD for Foreign Nationals) for a period of one year or 3000INR (100 USD for foreign Nationals) for a period of 5 Years. Members enrolled by both these programmes will have same access and privileges but will differ only by duration.

With receipt of certificate and payment, the member will within a span of one week receive a confirmation of Associate Membership with Membership Number. A personalized ID and PW will also be provided to access the website and services. In all further correspondence with IORG the member has to mention the Membership number to avail any service required. All services will be provided only for the duration of membership which will start from the day of confirmation of membership and will have to be renewed annually or 5 yearly as per the subscription chosen.

For any further information mail to us: indian.ortho@gmail.com

