Bilateral Femoral Nutrient Foraminal Cement Penetration during Total Hip Arthroplasty

Ross Coomber[1], Rej S Bhumbra[2], Robert Marston[3]

What to Learn from this Article?

What are the differential if you notice extra cortical cement around femoral shaft after THR?
Presentation and management of nutrient artery cement penetration?

Abstract

Introduction: Cement pressurisation is important for the insertion of both the acetabular and femoral components during Total Hip Arthroplasty (THA). Secondary to pressurization the rare phenomenon of unilateral cement incursion into the nutrient foramen has previously been reported. No bilateral case has been reported to date. This has implications both for misdiagnosis of periprosthetic fractures and for medico-legal consequences due to a presumed adverse intra-operative event.

Case Report: We present a case report of a 59 year old, caucasian female who underwent staged bilateral cemented Stanmore THA. The post-operative radiographs demonstrate evidence of bilateral nutrient foramen penetration intra-operatively by standard viscosity cement. The patient suffered no adverse consequences.

Conclusions: In summary, cement extravasation into the nutrient foramen is an important differential to be considered in presence of posterior-medial cement in the diaphysis of femur following THA. This requires no further intervention and has no effect on the outcome.

Keywords: Nutrient Foramen, Total Hip Arthroplasty, Cement, Polymethyl methacrylate.

Introduction

Our aim is to draw attention to the post-operative x-ray appearances of apparent cortical perforation by cement due to cement incursion into the nutrient foramen. This is a known rare phenomenon [1-5] but there is no report of a bilateral case. Hip arthroplasty surgeons need to be aware of this as a potential misdiagnosis of intra-operative periprosthestic fracture, which may result in unnecessary protected weight-bearing or subsequent surgical planning. There is also clearly a medico-legal implication to any presumed adverse intra-operative event.

Cement pressurisation on insertion of both the acetabular and femoral component, is important in order to achieve appropriate cement-bone micro-interloc for optimum component fixation [6]. In order to maximise cement-bone interdigitation, standard viscosity cement is inserted under pressure using a cement gun. Any cortical defects, such as a fracture, could allow extramedullary cement extrusion. The most common cause of extradiaphyseal cement found on a post-operative X-ray following THR is an iatrogenic

[1]Department of Orthopaedic Surgery. Luton and Dunstable Hospital, Lewsey Road, Luton, UK.
[2]London Sarcoma Service. Royal National Orthopaedic Hospital. Stanmore. London.
[3]Dept of Orthopaedics and Trauma. Bonney House. St. Mary's Hospital.Imperial College of Medicine,Norfolk Place. Paddington. London. UK
Address of Correspondence
Dr Ross Coomber
Orthopaedic Specialty Registrar –Department of Orthopaedic Surgery. Luton and Dunstable Hospital, 38a Packington St, London, N1 8QB. United Kingdom
Email: rosscoomber@hotmail.com

Author's Photo Gallery


Dr. Ross Coomber
Bsc., MBBS, MRCS


Dr. Rej S Bhumbra
PhD, FRCS (Orth).


Dr. Robert Marston
Bsc., FRCS, FRCS (Orth).

Figure 1 – AP pelvis showing right THR with cement extrusion

orthopaedic team into reducing or eliminating weight put through the leg, thereby prolonging patient rehabilitation. Cement penetration of nutrient foramen can have presentation similar to iatrogenic breach and should be considered as differential

Case Report

Patient (MC) was a 59 year old female presenting with bilateral hip Osteoarthritis. She underwent right-sided cemented Stanmore THR. The hip joint was exposed through the posterior approach. The femoral cavity was prepared, cleaned using pulse lavage and brushing, dried and a size 12.5 mm cement restrictor placed (cement plug JRI) two centimetres distal to the tip of the femoral component. After three to four minutes of polymerisation standard viscosity cement (Refobacin, Biomet) was introduced into the femoral cavity using 4th generation cementing techniques. A retrograde technique was employed with a suction catheter placed distally in the initial cementation period and a proximal cement pressurisation adapter for the cement gun was used. It was

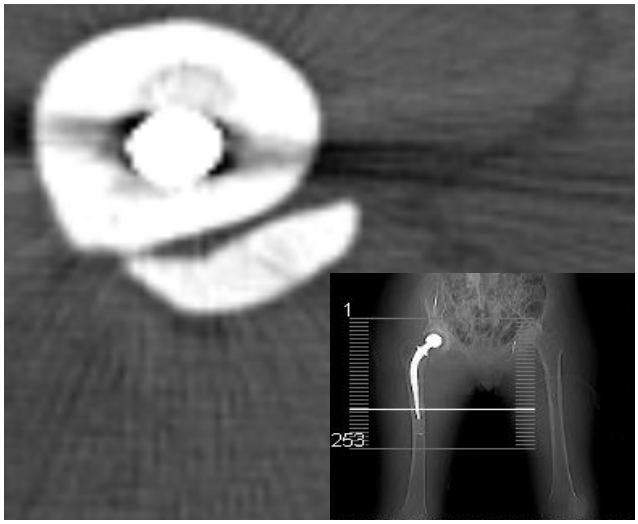

Figure 3 – CT of right femur showing extracortical cement

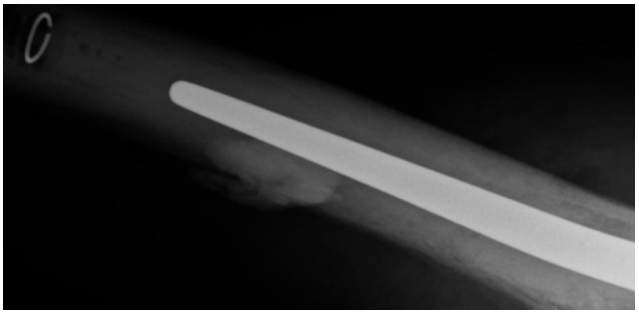

Figure 2 – Lateral of right femur showing cement extrusion

apparent that the gun (Stryker UK cement gun) nozzle, abutted the endosteum closely. No untoward intra-operative events were noted and the patient returned to the ward with no adverse features in the post-operative course.

A check X-ray of the procedure taken two days post-operatively demonstrated significant cement extrusion from the posterior-medial aspect of the femoral diaphysis approximately 2 cms (26.6 mm) proximal from the stem tip and 17mm extrusion into the soft tissues. (Fig. 1 & 2 AP and lateral of proximal femur, measurements took account of radiographic magnification). The patient had no adverse pain on mobilisation. A CT scan was requested which showed cement extrusion outside the femur cortex (Fig. 3). Given no report of pain on mobilisation and the absence of a definitive fracture line, cement extravasation was attributable to pressurisation through the nutrient foramen. Three months later the patient attended for contra-lateral surgery and underwent an identical procedure as the first hip. A similar, but not identical x-ray appearance was noted, (Fig. 4) with 8.5 mm cement extrusion out into the soft tissues and 4 cms (41mm) cement extrusion from the tip of the prosthesis. The patient was happy with the post-operative result and continued to make an uneventful and full recovery.

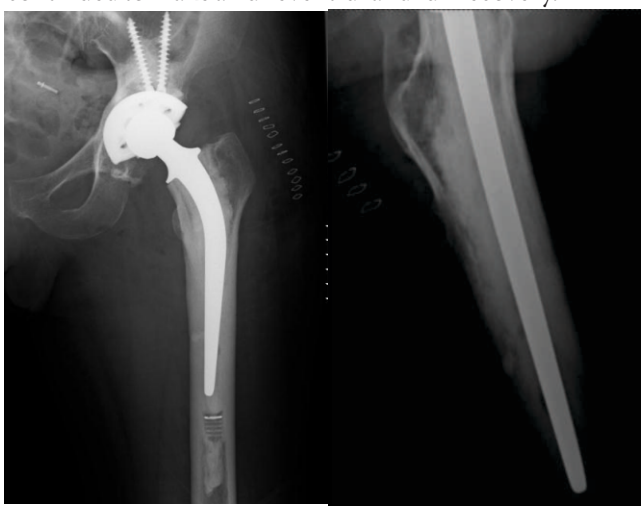

Figure 4: AP and Lateral views of left THR showing cement extrusion

Discussion

Factors most likely to result in cement extravasation into the nutrient foramen include less oblique and wide foramen and those associated with the cement itself such as high pressure. Our bilateral case was a female measuring 145 cm. Patient size associated with a narrow femur and the ability of the cement gun to occlude the medulla may increase local pressurisation considerably. It is noteworthy that of the 19 cases reported in the literature[1-5], 16 have occurred in females, hence it is reasonable to assume that a female preponderance does indeed exist. Gaucher's disease and β-thalassaemia have both been associated with enlarged nutrient foramina in phalanges [7] but no association is reported with regards to the femur. The patient was tested and found to be negative for these conditions.

The anatomical location of the nutrient artery has been proven to be relatively consistent [8]. Given cement extrusion at this level, the diagnosis of an iatrogenic cortical breech is unlikely. Some authors have suggested that morphological features of the extra-diasphyseal cement may help in differentiating vascular cement infiltration from cement extrusion secondary to fracture [3]. The appearances of both a thin line and localized cement mass have been reported in association with this phenomenon [5].

The literature supports the view that the long-term clinical implications of cement extrusion into the nutrient foramen is minimal [1-4]. Weismann felt the relationship of cement in the nutrient vasculature and clinical symptoms was less clear. The vetinary literature contains a study of radiographically diagnosed medullary infarction secondary to THR and relates this to nutrient vascular compromise [9].

Conclusion

In summary, cement extravasation into the nutrient foramen is an important differential to be considered in presence of posterior-medial cement in the diaphysis of the femur following total hip replacement.

Clinical Message

Cement extravasation into nutrient foramen has radiographic appearance similar to cement extrusion due to cortical perforation and should be differentiated. In itself it has a benign course and does not affect the outcome. No further action other than reassurance (of both patient and surgeon) is needed

References

1. *Knight JL. Coglon T. Hagan C. Clark J. Posterior distal cement Extrusion during Primary Total Hip Arthroplasty. A cause for concern? J Arthroplasty 1999;14(7):832-839.*

2. *Nogler M. Fischer M. Freund M. Mayr E. Bach C. Wimmer C. Retrograde Injection of a Nutrient Vein with Cement in Cemented Total Hip Arthroplasty. J Arthroplasty 2002;17(4):505-506.*

3. *Skyrme AD, Jeer PJS, Berry J, Lewis SG, Compson JP. Intravenous polymethacyrylate after cemented hemiarthroplasty of the hip. J Arthroplasty 2001;16(4):521-523.*

4. *Panousis K, Young KA, Grigoris P. Polymethylmethacrylate arteriography – A complication of total hip arthroplasty. Acta Orthop Belg 2006;72:226-8.*

5. *Weissman BN. Sosman JL. Braunstein EM. Dadkhahipoor H. Kandarpa. Thornhill. Lowell JD. Sledge C. Intravenous Mrthymethacrylate after Total Hip Replacement. JBJS [Am] 1984;66-A(3):443-450.*

6. *Learmonth ID, ed. Interface in total hip arthroplasty. London; Springer-Verlag Ltd, 2000*

7. *Fink IJ. Pastakia. Barranger JA. Enlarged phalangeal nutrient foramina in Gaucher disease and beta-thalassaemia major. Am. J. Roent 1984;143(3):647-649.*

8. *Farrouk O. Krettek C. Miclau T. Schandelmaier P. Tscherne H. The topography of the perforating vessels of the Deep Femoral Artery. Clin. Orth. 1999;368:255-259.*

9. *Sebestyen P. Marcellin-Little J. Deyoung BA. Femoral Medullary Infarction Secondary to Canine Total Hip Arthroplasty. Veterinary Surgery 2004;29:227-236.*

Conflict of Interest: Nil
Source of Support: None

How to Cite this Article:
Coomber R, Bhumbra RS, Marston R. Bilateral Femoral Nutrient Foraminal Cement Penetration during Total Hip Arthroplasty. Journal of Orthopaedic Case Reports 2012 Oct-Dec;2(4): 4-6