

An Unusual Disengagement of the Humeral Head Component after Hemiarthroplasty: A Case Report Presentation

Cuneyd Gunay¹, Fuad Oken¹, Ahmet Ozgur Yildirim¹, Ahmet Ucaner¹

What to Learn from this Article?

Rare Complication of Shoulder Hemiarthroplasty and its Management.

Abstract

Introduction: Proximal humeral fractures account for 4% to 5% of all fractures. Complex proximal humeral fractures with displaced three- and four- part fragments, humeral head splits and fracture-dislocations are more difficult to treat. In older patients, because of poor bone quality, hemiarthroplasty is often the indicated treatment.

Case Report: One such case of a 73-year-old woman is presented here. The patient presented with a four-part fracture of the proximal humerus, with displacement of the humeral head. Hemiarthroplasty was done in the right shoulder. At postoperative 20 days, during physical therapy, the humeral head component of the prosthesis disengaged and a second operation was necessary. A deltopectoral approach was repeated using the previous incision. The humeral stem was seen to be well-fixed into the bone so the humeral head was changed for a new one of the same size. At two years, the dominant right side had active, painless ROM.

Conclusion: The management and two-year follow-up of this case is reported here, which was the first to occur at our institution.

Keywords: Complications; fracture; proximal humerus; shoulder hemiarthroplasty; surgical treatment.

Introduction

Proximal humerus fractures account for approximately 5% of all extremity fractures which represent nearly 50% of all shoulder girdle injuries, and the incidence is higher in the elderly population [1]. Although performed with less frequency than hip and knee arthroplasties, the prevalence of shoulder arthroplasty has doubled in the last two decades as ageing populations increase. Patients older than 70 years

with severe fractures are candidates for arthroplasty [2].

Osteoporotic fractures in elderly patients are commonly associated with minor trauma such as ground-level falls. The indications for hemiarthroplasty (HA) include comminuted three- and four-part fractures with dislocation of the head, and fractures which split the head with involvement of more than 40% of the articular surface [3]. Primary humeral head replacement is a well accepted

Author's Photo Gallery



Dr. Cuneyd Gunay



Dr. Fuad Oken




Dr. Ahmet Ozgur Yildirim




Dr. Ahmet Ucaner

Reviewer's Photo Gallery



Dr. Ashok Shyam



Dr. Kunal Shah

¹Ankara Numune Training and Research Hospital, Department of Orthopaedic Surgery and Traumatology, Altındağ, Ankara, Turkey.

Address of Correspondence

Dr. Cuneyd Gunay, Ulku mah. Talatpasa Bulvarı No:5, PK:06100 Altındağ, Ankara, Turkey.
E-mail: cunganay@hotmail.com

treatment option for a variety of fractures of the proximal humerus and provides consistent pain relief [4]. Specific complications of shoulder arthroplasty include dislocation, fracture, joint stiffness, nerve injury, and detachment of the deltoid muscle. In the case presented here, an unusual disengagement of the humeral head component occurred three weeks after the index surgery. The presentation and management is reported here of this uncommon complication in a 73-year-old female. To the best of our knowledge there are no published reports of disengagement of the humeral head component after hemiarthroplasty of shoulder and its subsequent management.

Case Report

A 73-year-old right hand-dominant female patient was admitted to the emergency department of our hospital with severe pain in the right upper extremity following a fall at her home. Clinical examination determined painful and restricted range of motion of the shoulder, crepitus from the fracture fragments and extensive ecchymosis to the elbow on her right shoulder. No neurovascular impairment was found. From her history, we learned that she had only hypertension which is under control. Anteroposterior, lateral radiographs and computed tomography (CT) scanning of the right shoulder revealed a four-part fracture-dislocation of the proximal humerus [Fig 1]. The fracture type was graded using Neer's original classification [4].

Her arm was stabilized in arm slings, and surgical intervention was planned. Three days after admission, she underwent HA surgery. After proper induction of general anesthesia, the patient was placed in the beach chair position. A standard delto-pectoral approach was used to access the proximal humerus. Bone cement was used to fix

the nine mm humeral stem and then an artificial 44/17 mm humeral head prosthesis (Bio-modular® Shoulder System; Biomet Inc, USA) was positioned in approximately 20° of retroversion. The head was impacted and after it was checked with full manual effort for the security. The artificial head of the humerus was fitted into the glenoid cavity of the scapula, secured by the tendon of the long head of

the biceps brachii. The rotator cuff was realigned using 1.0 vicryl sutures. A hemovac drain was used and the wound was closed in anatomic layers. The operation was successfully performed, without any intraoperative complications [Fig 2]. The affected limb was suspended in a shoulder sling for six weeks. In first 3 weeks, only passive shoulder-joint activities (eg: pendulum exercises) were carried out, and active functional exercises of the ipsilateral hand, wrist, and elbow were initiated concurrently. After 3 weeks from the operation, under physiotherapist control, slightly active ROM exercises were started. Upper extremity lifting was avoided during the first six weeks [5]. Also these are our routine physiotherapy program after HA in our institution.

The patient was discharged from hospital one week postoperatively. After 20 days, she was re-admitted to our hospital suffering pain and deformity in the right shoulder. From the history, we learned that during physical therapy, she had experienced pain, discontinued the daily program and returned to hospital. On radiographic examination an unusual disengagement of the humeral head component of the prosthesis was detected [Fig 3]. We know that this complication has occurred in the first 20 days. This means, the patient was under passive ROM program. We could not learn from the physiotherapist that what maneuver is caused to this unusual disengagement. But we think that, during physiotherapy maybe a forceful activity was done and this unusual complication has occurred. The patient underwent a second surgical operation. A deltopectoral approach was repeated using the previous incision. During the operation, in addition to the disengagement of the component, hypertrophic biceps tendon was determined. We do not have any idea because of hypertrophic tendon, only we have seen it. The humeral stem was seen to be well-fixed into the bone

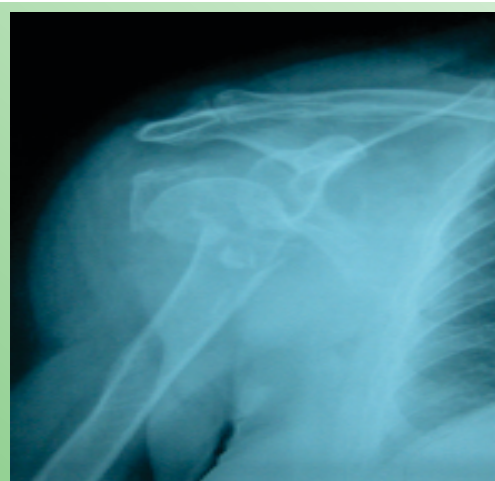

Figure 1: Antero-posterior Radiograph of a 73-year-old Female with a Neer's Four-part Fracture-dislocation Resulting from a Simple Fall.

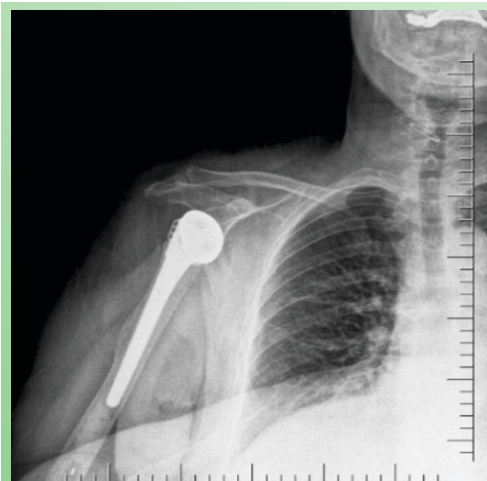


Figure 2: Immediate Post-operative X-ray Showing Satisfactory Cemented Hemiarthroplasty of the Right Shoulder.

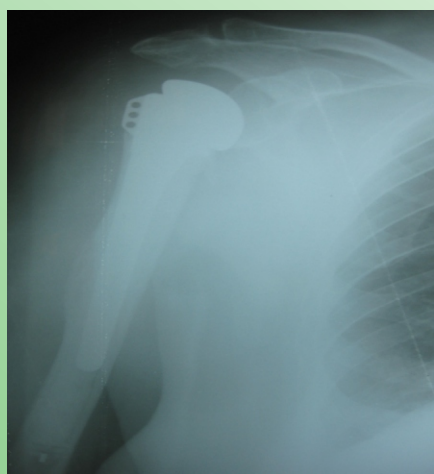


Figure 4: Antero-posterior Radiograph at 2-year Follow-up.

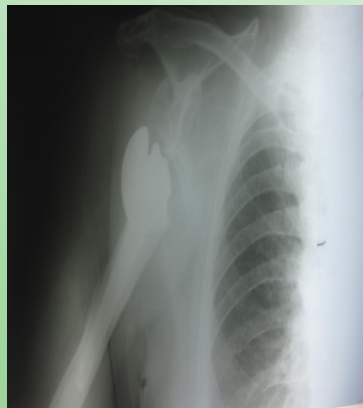


Figure 3: Antero-posterior Radiograph of the Shoulder Showing the Disengagement of the Humeral Head Component of the Prosthesis.

so the humeral head was changed for a new one of the same size. No relevant complications were encountered during surgery. When the patient was discharged, resistance rotation exercises were not allowed during the first postoperative six weeks. The patient was followed-up at one, three, six and ten weeks postoperatively and at three-month intervals thereafter. After the second surgery, the patient used a shoulder immobilizer for a period of four to six weeks with the arm kept in a neutral position. Passive motion was started four weeks later with active motion commencing after six weeks. At two years, the dominant right side had active, painless ROM of 120° of forward flexion, 90° of internal rotation, 90° of abduction, and 60° of external rotation in abduction. This was equivalent to the contralateral side, which had also undergone HA five years previously in our institution. The shoulder prosthesis had not failed [Fig 4].

Discussion

Shoulder arthroplasty remains a valuable solution for the treatment of non-reconstructable proximal humeral fractures in elderly patients [6]. Over 75% of all proximal humeral fractures occur in patients over 60 years of age and over 75% of all proximal humeral fractures occur in women [7,8]. However, the treatment of three- or four-part fractures and split head humeral fractures is an unresolved problem [9,10]. With continued advancements in the production of artificial joints and surgical techniques, hemiarthroplasty has become increasingly popular for treating comminuted fractures of the proximal humerus and has become the routine therapeutic approach for this type of fracture in many centers [11].

In literature, complications of shoulder hemiarthroplasty

are known to be superior and posterior migration of the greater tuberosity, nonunion between the tuberosities and the diaphysis, bone resorption of the greater tuberosity, rotator cuff failure, periprosthetic fracture, nerve lesions, luxation of the prosthesis, heterotopic ossification and deep infection [2,12]. However, the disengagement of the humeral head component of the prosthesis is uncommon and has not been previously reported.

Postoperative rehabilitation remains a matter of debate. A sling is generally recommended for four weeks to six weeks, with early passive rehabilitation to avoid stiffness. The purpose of slings is to

provide support, decrease dependent edema, and increase comfort for the patient. The resting position in internal rotation in the sling induces greater tuberosity traction, so that some authors prefer immobilization in neutral or slight external rotation to limit the risk of tuberosity migration in elderly or osteoporotic patients [13]. We think that muscle strengthening against resistance should be initiated after 3 months. Robinson et al. [3] reported that clinical results are definitive at six months, although other authors recommend continuing muscle strengthening for up to one year [14].

Instability may result if the humeral component is placed too high or too low, resulting in secondary impingement or poor soft tissue tension, respectively. Humeral head height has been reported to have a positive correlation with the outcome, whereas medial calcar offset has been negatively correlated with the final outcome. Most patients with three or four part fractures have comminution in the calcar region, so that humeral head height is technically more difficult to assess than offset during surgical intervention [15]. Improper placement of the component in excessive anteversion or retroversion may also lead to dislocation [2,16]. In addition to these points, there is a general belief that the humeral stem should be fixed with cement to obtain rotational stability and proper positioning of the prosthesis [17]. In the case presented here, there were no implant position related problems.

It is thought that the results of HA depend mostly on the patient's age, and adequate rehabilitation. HA is indicated in patients who are medically stable, can tolerate extensive surgery, and are able to participate in a postoperative rehabilitation program. Systematic and correct rehabilitation exercises are highly important for optimal recovery of

shoulder function. Postoperative functional exercise should be carried out in an ordered manner. Active exercise should occur after passive exercise, the angle should be increased gradually, and the exercise should be performed for each individual attentively [5,17].

It is necessary to ensure that the patient understands the non-weight-bearing activity limitations: no active internal and external rotation, and no shoulder extension beyond neutral. The patient must avoid putting weight on the affected arm and using the arm to push up from a sitting position. The operated arm must not be used actively or to lift objects until instructed by the surgeon.

Clinical Message

The disengagement of the humeral head component of the prosthesis is uncommon and has not been previously reported. Systematic and correct rehabilitation exercises are highly important for optimal recovery of shoulder function. Postoperative functional exercise should be carried out in an ordered manner. Also the motivation of the patient is especially important for the treatment success.

Conclusion

Dislocation of an artificial joint and also only disengagement of the humeral component from the stem may occur. There is an increased risk of dislocation after surgery and during the healing process, which is why activity is restricted and a shoulder immobilizer is used. The motivation of the patient is especially important for the treatment success. It should be noted that no active muscular activity was started until a complete range of passive movement had been achieved.

References

1. Nordqvist A, Petersson CJ. Incidence and causes of shoulder girdle injuries in an urban population. *J Shoulder Elbow Surg* 1995;4:107-12.
2. Krishnan SG, Bennion PW, Reineck JR, Burkhead WZ. Hemiarthroplasty for proximal humeral fracture: restoration of the Gothic arch. *Orthop Clin North Am* 2008;39:441-50.
3. Robinson CM, Page RS, Hill RM, Sanders DL, Court-Brown CM, Wakefield AE. Primary hemiarthroplasty for treatment of proximal humeral fractures. *J Bone Joint Surg Am* 2003;85-A:1215-23.
4. Neer CS 2nd. Displaced proximal humeral fractures. I. Classification and evaluation. *J Bone Joint Surg Am* 1970;52:1077-89.
5. Cohen BS, Romeo AA, Bach BR. Shoulder injuries. In: Brozman SB, Wilk KE, editors. *Clinical Orthopaedic Rehabilitation*, Philadelphia: Mosby; p 125-250, 2003.
6. Gamradt SC, Gelber J, Zhang AL. Shoulder function and pain level after revision of failed reverse shoulder replacement to hemiarthroplasty. *Int J Shoulder Surg* 2012;6:29-35.
7. Anjum SN, Butt MS. Treatment of comminuted proximal humerus fractures with shoulder hemiarthroplasty in elderly patients. *Acta Orthop Belg* 2005;71:388-95.
8. Jakob RP, Miniaci A, Anson PS, Jaberg H, Osterwalder A, Ganz R. Four-part valgus impacted fractures of the proximal humerus. *J Bone Joint Surg Br* 1991;73:295-8.
9. Lanting B, MacDermid J, Drosdowech D, Faber KJ. Proximal humeral fractures: a systematic review of treatment modalities. *J Shoulder Elbow Surg* 2008;17:42-54.
10. Vallier HA. Treatment of proximal humerus fractures. *J Orthop Trauma* 2007;21:469-76.
11. Wiggins AJ, Roolker W, Patt TW, Raaymakers EL, Marti RK. Open reduction and internal fixation of three and four-part fractures of the proximal part of the humerus. *J Bone Joint Surg Am* 2002;84-A:1919-25.
12. Green A, Barnard WL, Limbird RS. Humeral head replacement for acute, four-part proximal humerus fractures. *J Shoulder Elbow Surg* 1993;2:249-54.
13. Boileau P, Krishnan SG, Tinsi L, Walch G, Coste JS, Molé D. Tuberosity malposition and migration: reasons for poor outcomes after hemiarthroplasty for displaced fractures of the proximal humerus. *J Shoulder Elbow Surg* 2002;11:401-12.
14. Sirveaux F, Roche O, Molé D. Shoulder arthroplasty for acute proximal humerus fracture. *Orthop Traumatol Surg Res* 2010;96:683-94.
15. Solberg BD, Moon CN, Franco DP, Paiement GD. Surgical treatment of three and four-part proximal humeral fractures. *J Bone Joint Surg Am* 2009;91:1689-97.
16. Hempfing A, Leunig M, Ballmer FT, Hertel R. Surgical landmarks to determine humeral head retrotorsion for hemiarthroplasty in fractures. *J Shoulder Elbow Surg* 2001;10:460-3.
17. Plausinis D, Kwon YW, Zuckerman JD. Complications of humeral head replacement for proximal humeral fractures. *Instr Course Lect* 2005;54:371-80.

Conflict of Interest: Nil
Source of Support: None

How to Cite this Article:

Gunay C, Oken F, Yildirim AO, Ucaner A. An Unusual Disengagement of the Humeral Head Component after Hemiarthroplasty: A Case Report Presentation. *Journal of Orthopaedic Case Reports* 2014 April-June;4(2): 69-72