

# A Case Report about Early Major Postoperative Ossifications of the Shoulder

Maurice Kouame<sup>1</sup>, Moctar Traore<sup>1</sup>, Armand Yepie<sup>1</sup>, Michel Anoumou<sup>1</sup>

## What to Learn from this Article?

Surgical resection of posttraumatic heterotopic ossifications of the shoulder must be practiced only if they impact the joints function.

## Abstract

**Introduction:** Ossifications after osteosynthesis of the proximal humerus are poorly described. We report a case of major and early ossifications after synthesis of a fracture dislocation of the shoulder.

**Case Report:** A 57-year-old man, right-handed, bipolar schizophrenic, presented after a fall, a fracture of the head and metaphysis of the humerus from the anterior notch of posterior dislocation of the right humerus. An osteosynthesis was performed after reduction on the tenth posttraumatic day. The postoperative period was complicated because of early ossifications and painless stiffness of the shoulder.

**Conclusion:** The importance of local trauma, the long consultation period, the operative difficulties and the heparin therapy are factors that could have favored the occurrence of ossifications. Preventive treatment could have prevented them or limited their extent.

**Keywords:** Heterotopic ossification, humerus, shoulder, surgery.

## Introduction

Ossifications were described for the first time in the shoulder, according to Erggelet *et al.* [1] by Smith in 1835 and are rather the consequence of arthroplasty [2]. Several predisposing factors have been described [3]. They are rare after synthesis of the proximal humerus and compromise little the functional prognosis of the shoulder [4].

Our objective is to report the observation of major and early ossifications after osteosynthesis of a fracture dislocation of the humeral head and make a review of the literature.

## Case Report

Mr. K. F. a 57-year-old man, right-handed, bipolar schizophrenic, was the victim of a mechanical fall from standing height. On admission, neurological examination was normal. A painful strain evoked a broken left wrist. The right shoulder was swollen, painful and nonfunctional. Radiography objectified anterior marginal fracture of the distal radius and fracture of the proximal humerus with suspected posterior dislocation associated (Fig. 1). The computed tomography scan confirmed the diagnosis of complex proximal humeral fracture associated with posterior

## Author's Photo Gallery



Dr. Maurice Kouame



Dr. Michel Anoumou

## Access this article online

Website:  
[www.jocr.co.in](http://www.jocr.co.in)

DOI:  
2250-0685.582

Department of Orthopaedics, Treichville Teaching Hospital, (Abidjan/Ivory Coast), PO Box V 3 Abidjan 01.

## Address of Correspondence:

Dr. Maurice Kouame,  
Department of Bone and Joints, University Félix Houphouët-Boigny, P.O. Box 440, Cocody, Abidjan, Ivory Coast.  
**E-mail:** [khamaurice@yahoo.fr](mailto:khamaurice@yahoo.fr)

Copyright © 2016 by Journal of Orthopaedic Case Reports

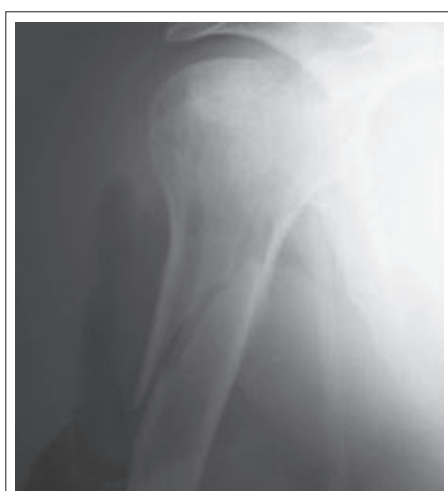Journal of Orthopaedic Case Reports | pISSN 2250-0685 | eISSN 2321-3817 | Available on [www.jocr.co.in](http://www.jocr.co.in) | doi: [10.13107/jocr.2250-0685.582](https://doi.org/10.13107/jocr.2250-0685.582)

This is an Open Access article distributed under the terms of the Creative Commons Attribution Non-Commercial License (<http://creativecommons.org/licenses/by-nc/3.0>) which permits unrestricted non-commercial use, distribution, and reproduction in any medium, provided the original work is properly cited.

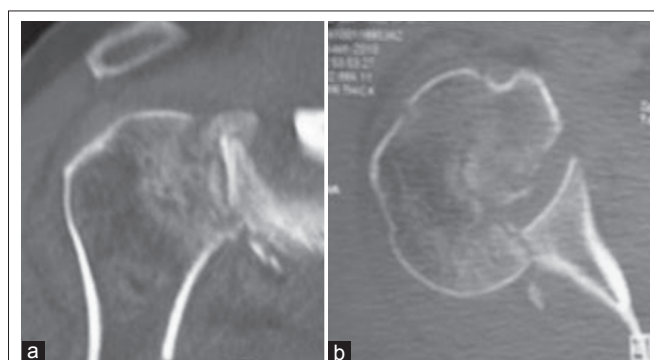dislocation of the humeral head. This was a fracture in four fragments of Neer associated with posterior dislocation or fracture of the head and metaphysis of the humerus from the anterior notch of posterior dislocation in reference to Duparc classification [5]. An anteroinferior marginal fracture of the glenoid (Fig. 2a and b) was associated.

An osteosynthesis of the wrist bone was carried out in an emergency. Ten days later, the synthesis of the humeral fracture was performed by the extended deltopectoral approach. The minor tubercle held up, the long biceps broken is resected and undergoes tenodesis in its groove. The humeral cap united to the metaphyseal-diaphyseal posteromedial beak is reduced then screwed in compression. We fix again the fragment of the major tubercle fractured by osteosuture and the minor tubercle is screwed into the cephalic notch. The synthesis is carried out by a small fragment locking compression plate. The incision is closed over a suction drain. The limb is held by a derotation device. Analgesic treatment, preventive heparin therapy were prescribed. The immediate postoperative course was uneventful and the control radiography satisfactory (Fig. 3a and b). Healing was obtained in the normal time. Rehabilitation started on the 4<sup>th</sup> day by assisted passive and active mobilization, joint and muscle maintenance. The derotation system is kept between sessions for 5 weeks.

The discharge from the hospital was carried out 28 days after shoulder surgery. Three weeks later, the radiography showed ossifications with Grade 3 glenoid starting point according to Kjaersgaard-Andersen *et al.*



**Figure 1:** X-ray of the right shoulder: Single incidence.



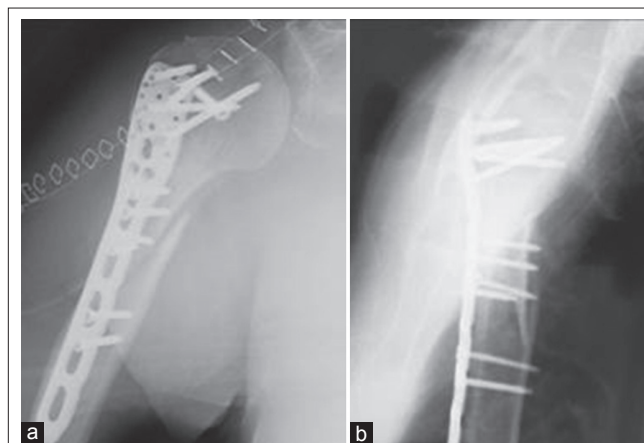**Figure 2:** (a and b) Scanner of the shoulder: Fracture-dislocation, fracture of the glenoid, and anterior notch of the humeral head.

(Fig. 4a) [6]. Successive checks confirmed ossifications (Fig. 4b and c). Six months later, the shoulder was stiff and painless with active anterior elevation to 70°, active abduction to 45°, external rotation nil and thumb to the right buttock in internal rotation. The hand-mouth was possible, and the hand-head was the limit. Glenoid humeral ossifications were identical (Fig. 4d).

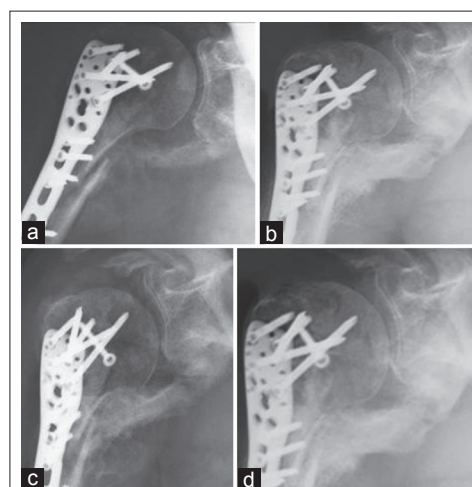
## Discussion

Ossifications after osteosynthesis of the proximal humerus are reported in a proportion of 0-10% [4, 7]. Males would be predisposed to them [3, 8] without any preferred age unlike the hip where the 60s are more exposed [6]. Our patient is a 57-year-old man.

Their occurrence mechanism is still unclear [2, 3, 9]. Hereditary and acquired factors, trauma and certain treatments such as heparin therapy might predispose to their formation [1, 3, 4, 7, 9, 10, 11, 12]. The operative difficulties and the intervention beyond 10 days due to the transformation of the hematoma around the fracture may increase the risk [1, 12]. We still ignore the possible role of immobilization and rehabilitation in the process of periarticular ossification after surgery [1]. Some of these



**Figure 3:** (a) Face postoperative X-ray control. (b) Profile postoperative X-ray control.



**Figure 4:** Postoperative ossifications. (a) To 3 weeks, (b) To 6 weeks, (c) To 3 months, (d) To 6 months.

factors exist in our patient. The importance of local trauma is certain. The intervention was carried out within 10 days and was quite difficult with enlargement of the approach. These factors coupled with the heparin therapy could justify ossifications. Moreover, the neurological origin cannot be discussed because there is no notion of head trauma or coma. We have no knowledge of a study incriminating schizophrenia in ectopic osteogenesis.

The therapeutic indications in proximal humerus fractures are a matter of debate. What is important is to find the indication that adapts to the patient's needs and to obtain the support of the latter for the treatment chosen [7]. The lesion in our patient is a particular form because of low risk of necrosis according to Favard *et al.* [13]. Treatment is conservative.

Our indication of osteosynthesis seems perfectly licit. The correct reconstruction of the fracture confirms our choice. In addition, ossifications are more frequent in prosthetic shoulder with rates ranging up to 45% [2] than in synthesis.

Pre- and post-operative external radiotherapy and nonsteroidal anti-inflammatory drugs (NSAIDs) are two preventive methods of postoperative ossifications. For the NSAIDs, indomethacin molecule is usually used in three daily doses of 25 mg from the 1<sup>st</sup> operative day to 6-12 weeks. According to Zouhair *et al.* [14], it was used for the first time in 1975 by DALH in higher doses. Its prescription is limited by its gastrointestinal complications and contra-indication in renally impaired subjects. For radiotherapy, protocols are quite varied. However, in recent studies [15], two patterns seem to be accepted. This is, on the one hand, the single preoperative irradiation of seven to eight grays, 4 h before surgery, and on the other hand, the single irradiation at the same dose until the 4<sup>th</sup> postoperative day. Their effectiveness is essentially identical [14, 15]. The major complication of radiotherapy is the occurrence of cancer that single doses seem to minimize.

Radiation therapy and NSAIDs work by the same biochemical and cytological mechanisms. They prevent the formation of osteoblastic cells by inhibiting the differentiation of mesenchymal cells, thereby preventing the formation of ectopic bone. With very different side effects, external radiotherapy and NSAIDs are equally effective [3, 8, 10, 14, 15]. The choice of one or other of the methods depends on the therapist and takes into account the patient's organism and the therapeutic cost. On this latter criterion, indomethacin is recognized more accessible. In our clinical case

report, indomethacin was the most accessible means that we should have prescribed in the prevention of the postoperative period.

Ossifications appear between 4 and 12 weeks, and their formation is not gradual [2]. The biological process of their formation starts as soon as the 16<sup>th</sup> posttraumatic hour, peaking between 36 and 48 h [8, 10]. Their diagnosis is accessible on the radiography between 3 and 6 weeks. In our patient, they formed very early, as they were already visible on radiographies 3 weeks postoperatively. They remained stable for 6 months, confirming the results mentioned above.

Ossifications are rarely painful and little influence joint function [2, 12]. Sanders *et al.* [9] advocate their surgical resection and arthrolysis coupled to a preventive treatment of recurrences when they are aggressive either through pain or by mechanical action on the joint. For Plausinis *et al.* [12], surgical treatment is licit, provided that the patient has objective limitations of joint mobility. Our patient presents a fairly limited articular mobility, but he seems to adapt to it from the point of view of the gestures of everyday life. He does not complain of any pain. We, therefore, believe that there is no need to intervene again immediately.

### Conclusion

Heterotopic ossifications following osteosynthesis of the proximal humerus are poorly reported. It is important to know the contributing factors and seek them faced with a complex fracture of the shoulder to institute a prophylactic treatment. Their surgical resection is discussed if they are aggressive and painful and is subject to a morphological assessment and a careful surgical planning to maturity.

### Clinical Message

Even if heterotopic ossifications following osteosynthesis of the proximal humerus are poorly reported, precautions to avoid them must be taken, when the contributing factors exist. The diagnosis of those factors is imperative in front of joints trauma. When diagnosed, the surgical resection of heterotopic ossifications needs a careful surgical planning and must respect functional needs of the patient.

### References

1. Erggelet C, Eggensperger G, Steinwachs M, Lahm A, Reichelt A. Postoperative ossifications of the shoulder. Incidence and clinical impact. *Arch Orthop Trauma Surg* 1999;119(3-4):168-70.
2. Sperling JW, Cofield RH, Rowland CM. Heterotopic ossification after total shoulder arthroplasty. *J Arthroplasty* 2000;15(2):179-82.
3. Kienapfel H, Koller M, Wüst A, Sprey C, Merte H, Engenhart-Cabillic R, *et al.* Prevention of heterotopic bone formation after total hip arthroplasty: A prospective randomised study comparing postoperative radiation therapy with indomethacin medication. *Arch Orthop Trauma Surg* 1999;119(5-6):296-302.
4. Connor PM, Flatow EL. Complications of internal fixation of proximal humeral fractures. *Orthopaedics* 2002;25(11):1255-7.
5. Vandenbussche E, Hutten D. Fractures of the proximal extremity of the humerus. *Med and Surg Encycl (Elsevier, Paris) Musculoskeletal System* 14-038-A-10;2000:20.
6. Kjaersgaard-Andersen P, Frich LH, Søbjerg JO, Sneppen O. Heterotopic bone formation following total shoulder arthroplasty. *J Arthroplasty* 1989;4(2):99-104.
7. Dimakopoulos P, Panagopoulos A, Kasimatis G. Transosseous suture fixation of proximal humeral fractures. *J Bone Joint Surg Am* 2007;89(8):1700-9.
8. Seegenschmiedt MH, Martus P, Goldmann AR, Wölfel R, Keilholz L, Sauer R. Preoperative versus postoperative radiotherapy for prevention of heterotopic ossification (HO): First results of a randomized trial in high-risk patients. *Int J Radiat Oncol Biol Phys* 1994;30(1):63-73.

9. Sanders BS, Wilcox RB 3<sup>rd</sup>, Higgins LD. Heterotopic ossification of the deltoid muscle after arthroscopic rotator cuff repair. *Am J Orthop* (Belle Mead NJ) 2010;39(7):E67-71.
10. Moore KD, Goss K, Anglen JO. Indomethacin versus radiation therapy for prophylaxis against heterotopic ossification in acetabular fractures: A randomised, prospective study. *J Bone Joint Surg Br* 1998;80(2):259-63.
11. Chao ST, Lee SY, Borden LS, Joyce MJ, Krebs VE, Suh JH. External beam radiation helps prevent heterotopic bone formation in patients with a history of heterotopic ossification. *J Arthroplasty* 2006;21(5):731-6.
12. Plausinis D, Kwon YW, Zukermann JD. Complications of humeral head replacement for proximal humeral fractures. *J Bone Surg Am* 2005;87(1):204-13.
13. Favard L, Berhouet J, Bacle G. Surgical treatment of fractures of the proximal extremity of the humerus in adult. *Med and surgical Encycl* (Elsevier, Paris). *Surg tehn Orthopaedics Traumatol* 2010;44-290:13.
14. Zouhair A, Ozsahin M, Mouhsine E, Leyvraz PF, Mirimanoff RO, Coucke PA. External radiotherapy or non-steroidal anti-inflammatory drugs for prevention of heterotopic ossification following total hip replacement. *Schweiz Med Wochenschr* 1999;129(9):370-6.
15. Nasr E, Nehme R, Ghanem I, Azoury F, Nasr DN. Role of the radiotherapy in h  terotopic ossifications. *Cancer Radiother* 2009;13(1):42-6.

Conflict of Interest: Nil  
Source of Support: None

#### How to Cite this Article

Kouame M, Traore M, Yepie A, Anoumou M. A Case Report about Early Major Postoperative Ossifications of the Shoulder. *Journal of Orthopaedic Case Reports* 2016 Sep-Oct;6(4): 80-83.