Bilateral Total Hip Arthroplasty in 20 Years Old Female with Neglected Developmental Dysplasia of Hip

Saurabh Agarwal[1], Jitesh K Jain[1], Rajeev K Sharma[1]

What to Learn from this Article?

Tips and Tricks of Performing THR in DDH.

Abstract

Introduction: Management of developmental dysplasia of hip in adult is challenging problem. Management protocols are not well defined in terms of operative technique. Patient may present very late. Usually they consult orthopaedic surgeons when osteoarthritic changes set in, leading to pain. Operative management is difficult because of difficult exposure, altered anatomy of soft tissue structures, hypoplastic femoral medullary canal and shallow and atypical acetabulum filled with soft tissues. Femoral head is up-ridden with contracted Abductors which resists reduction of femoral head into acetabulum. Altered anatomy of neurovascular structures also pose a risk of being injured during surgery.

Case Report: Here we are presenting a case of bilateral total hip arthroplasty in 20 years old female with developmental dysplasia of hip and sharing our experience of its operative management.

Conclusion: We concluded from this case study that total hip arthroplasty in developmental dysplasia of hip is technically demanding but gives good functional and clinical result. For getting functionally good result contracted soft tissues around joint need special attention.

Keywords: Developmental dysplasia of hip, Total hip arthroplasty, THR in DDH.

Introduction

Developmental dysplasia of hip is a spectrum of developmental disorders of hip in which acetabulum is dysplastic and it presents in different forms in different ages. Ligament laxity, breech position in utero and primary acetabular dysplasia has been suggested as etiological factors. If hip remains dislocated for a long time, fatty tissue (pulviner) thickens in the depth of acetabulum, ligamentum teres elongates and thickens and capsule gets stretched out and become very loose [1]. Acetabular cavity gradually flattens and medial wall thickens. Subluxated hip always leads to symptomatic hip disease. Symptoms may start in 2nd, 3rd or 4th decade of life. A completely dislocated hip usually causes symptoms much later than a subluxated hip

Author's Photo Gallery

Dr. Saurabh Agarwal

Dr. Jitesh K Jain

Dr. Rajeev K Sharma

Reviewer's Photo Gallery

Dr. Aditya Pathak

Dr. Chittaranajan Patel

[1]Department of Orthopaedics, Indraprastha Apollo Hospital, Sarita Vihar, Delhi Mathura Road, New Delhi – 110076. India.

Address of Correspondence
Dr. Jitesh Kumar Jain, Department of Orthopaedics, Indraprastha Apollo Hospital, Sarita Vihar, New Delhi – 110076. India.
Phone No. +91-879535946. E-mail: dr.jiteshajmera@yahoo.com

Journal of Orthopaedic Case Reports | pISSN 2250-0685 | eISSN 2321-3817 | Available on www.jocr.co.in | doi:10.13107/jocr.2250-0685.160

Figure 1: Pre-op X-rays.

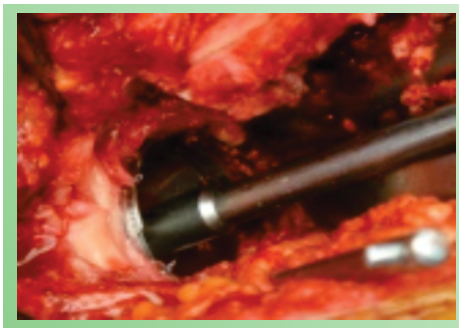

Figure 2: Picture Showing Near Complete Coverage of Acetabular Implant.

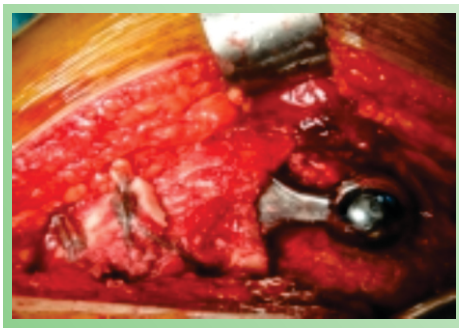

Figure 3: Osteotomy Site Re-inforced with Strut Graft with Cables.

and in some individual it never becomes painful.

Crowe et al [2] devised a popular classification to grade the severity of developmental dysplasia of hip which ranges from type one (superior migration of head <50%of its diameter) to type four (> 100% superior migration). Type four (as is the case in this patient) has worst functional outcome.

In cases of untreated developmental dysplasia of hip in adults, total hip arthroplasty (THA) is a challenging surgery. Anatomy is distorted; careful dissection is needed for exposure.

Acetabulum is usually hypoplastic with formation of false acetabulum. Locating a true acetabulum is important. Acetabular reconstruction is traditionally done with cemented or uncemented cup with or without structural bone grafting. Femoral head is up-ridden and femoral canal will also be hypo-plastic.

Joint capsule will be contracted which hampers the sufficient exposure of the joint and mobilization of femur. Femoral head has to be brought to the level of reconstructed acetabulum. This can be done by, careful dissection of soft tissues and release of capsule attached to the proximal femur, pi-crusting of abductors to gain length and if needed sub-trochanteric shortening of femur. Dysplastic hips are considered difficult cases for total hip arthroplasty. We are reporting this case for the good result we obtained with proper operative technique.

Case Report

A 20 years old female presented to us with history of difficulty in walking since childhood and pain in both hips for last two years. She had been suffering from these problems since childhood but had not taken any definitive treatment.

On examination patient was walking with waddling gait. All hip movements were painfully restricted and extension, adduction and rotational movements were not possible. 15^0 and 20^0 flexion deformities were present on right and left sides respectively. 20^0 and 10^0 Abduction deformities were present on right side and left side respectively. 3 centimeters shortening was present on left side.

On radiological examination X-ray pelvis with both hips AP view [Fig.1] revealed proximally migrated dysplastic head of femur with dysplastic shallow empty acetabulum. Acetabular angles on both sides were 60 degree.

Operative technique:

Preoperative planning included templating to determine position of acetabulum and required length of osteotomy. The length of subtrochantric osteotomy was determined so that it would not lengthen the leg more than 3 cm to prevent sciatic nerve stretching. All necessary investigations were done and anesthetic clearance was taken. Patient was planned for Bilateral Uncemented THA in two stages. Patient was positioned in Lateral position. Hip joint was approached by a postero-lateral incision over posterior aspect of greater trochanter curved over buttock. Exposure in such cases are

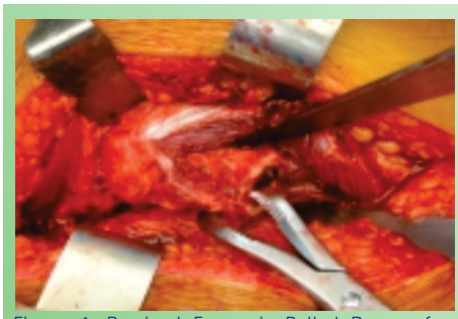

Figure 4: Proximal Femur is Pulled Down after Lengthening of Abductors and Soft Tissue Release.

Figure 5: Post-op X-ray after Right THA.

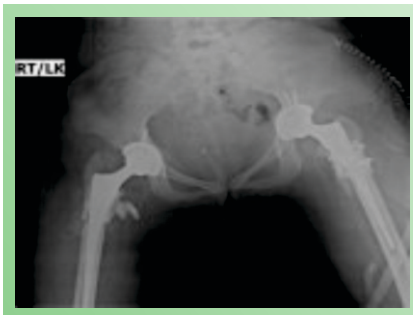

Figure 6: Post-op X-ray after Left THA.

Figure 7: 4 Months Follow-up X-ray Showing Good Callus Formation at Osteotomy Site.

challenging because of distorted anatomy. Soft tissues are contracted with tight adhesions. It should be kept in mind, that femoral neuro-vascular bundle and sciatic nerve may not be present at usual anatomic positions. After splitting gluteus maximus, external rotators were cut to reach the hip joint.

True acetabulum was identified by direct palpation and using C-ARM. Acetabulum was cleared of fibrous tissues and progressively large reamers were used to enlarge the shallow acetabulum. Using power reamer it was shaped spherical and a trial implant was used to determine the coverage of the cup. Ischial and pubic bone were exposed proximally along with tear drop to get a clear idea of available bone stock. Medial wall was sufficient to re-shape a proper Acetabulum. No structural Bone Grafting was required in Acetabular reconstruction. Appropriate diameter uncemented modular acetabular prosthesis was used. Acetabulum was stable and well seated per-op with coverage of more than 90% [Fig.2].

A sub trochanteric femoral osteotomy of five centimeters was done to facilitate the reduction. Osteotomized segment was vertically splitted and used to re-enforce osteotomy site as a cortical strut graft. It was stabilized with cables [Fig.3]. Excessive ante version of femoral neck was corrected by placing the prosthesis eccentrically in the medullary canal. To facilitate the reduction the proximal femur was pulled down by thorough soft tissue release [Fig.4]. Capsule and iliopsoas tendon were released and abductors were lengthened by pi crusting. The prosthetic joint than can be reduced without undue tension [Fig.5]. Left hip was reconstructed using similar technique after two weeks [Fig. 6]. We used acetabular Cup (Stryker) 44mm (both side), Head (Smith Nephew) 28mm (metal, both side) and femoral Stem (Smith Nephew) Size ten on Right side and Size nine on left side.

Result

Patient had uneventful recovery in the post-operative period. Physiotherapy in bed was started the next day after surgery. Patient was mobilized with support four weeks after surgery.

X-rays at four months follow-up showed good stable implants with good callus formation at the osteotomy sites [Fig. 7]. There was no limb length discrepancy in follow ups.

Discussion

In untreated developmental dysplasia of hip, concentric reduction of prosthetic hip is technically demanding. Cup coverage and restoration of normal hip biomechanics remain the most important issues. Acetabulum is hypoplastic with narrow femoral medullary canal. Anatomy and biomechanics are altered with excessive anteversion and defective abductor mechanism. A wide range of prostheses should be available to choose one which is best suited for hypoplastic bones.

Different views have been put forward regarding optimal position for acetabular reconstruction. We reconstructed acetabulum at the anatomical position. It restores the biomechanics near normal and best bone stock is available here. Although, Russoti and Harris have postulated that a proximal position of acetabulum is an acceptable alternative [3]. On the contrary, Pagnano et al. have found high rate of loosening of prosthetic components with proximal position [4]. Bone stock is also deficient proximally and restoration of normal hip biomechanics is difficult.

With reconstruction of acetabulum at anatomical site, femoral shortening is necessary for concentric reduction of femoral head. This also avoids the possibility of traction injury to sciatic nerve. We did subtrochanteric osteotomy in this case and osteotomized segment was vertically splitted and used to re-enforced osteotomy site as a cortical strut graft. It was stabilized with cables. Similar technique has also been used by Yasgur et al [5].

Reikeraas et al [6] obtained 96% good to excellent results with simple transverse osteotomy and fixation with porous coated stem. A subtrochanteric osteotomy along with modular stem allows for correction of excessive femoral anteversion as well as concentric reduction and also safeguards neurovascular structures against traction injury. Many authors [7] have shown satisfactory results with use of cemented stem in dysplastic femora. Keeping the young age of our patient and hypoplastic femoral canal in mind, we used uncemented modular stem in hope for better fixation and longer life of Implant. Lai et al [8] has also produced excellent results using cementless prostheses.

Anatomical reduction of prosthetic components can be possible only after lengthening of shortened abductors. In this case we did pie crusting of abductors to gain satisfactory length.

Structural bone grafting is traditionally done in acetabular reconstruction to reinforce deficient supero-lateral aspect. In this patient we obtained> 90% acetabular cup coverage on both sides [Fig 3] without structural bone grafting. Shinar A

et al. [9] have reported high failure rates in long term with use of Structural graft and recommended its use only as a last resort. Acetabular reconstruction has high failure rate if graft covers a large proportion of the cup. Although some authors have reported satisfactory results using structural bone graft [10, 11]. Leela C. Biant et al [12] reported excellent results in Crowe type three and four dysplastic hips at 10 years follow up using S-ROM stem. 21 of 28 patients in his case series required autologous bone grafting. We think that whenever bone stock permits cementless cup fixed with screws without structural bone grafting gives good result.

Conclusion

Total Hip Arthroplasty in untreated developmental dysplasia of hip is a technically demanding procedure and anatomical reconstruction of hip joint requires experience and technical support to provide pain free functionally good hip.

Clinical Message

Preoperative planning regarding acetabular position, proper prosthesis selection and adequate soft tissue dissection especially tight abductors and flexors are keys to success in these difficult cases.

References

1. *Ponseti IV. Morphology of the acetabulum in congenital dislocation of the hip: Gross histological and roentgenographic studies. J Bone Joint Surg Am 1978; 60:575.*
2. *Crowe JF, Mani VJ, Ranawat CS. Total hip replacement in congenital dislocation and dysplasia of the hip. J Bone Joint Surg [Am]1979; 61-A:15-23.*
3. *Russotti GM, Harris WH. Proximal placement of the acetabular component in total hip arthroplasty. A long-term follow-up study. J Bone Joint Surg Am 1991; 73:587–592.*
4. *Pagnano W, Hanssen AD, Lewallen DG, Shaughnessy WJ. The effect of superior placement of the acetabular component on the rate of loosening after total hip arthroplasty. J Bone Joint Surg Am 1996; 78:1004–1014.*
5. *Yasgur DJ, Stuchin SA, Adler EM, DiCesare PE. Subtrochanteric femoral shortening osteotomy in total hip arthroplasty for high-riding developmental dislocation of the hip. J Arthroplasty 1997;12:880-888.*
6. *Reikeraas O, Lereim P, Gabor I, Gunderson R, Bjerkreim I. Femoral shortening in total arthroplasty for completely dislocated hips: 3-7 year results in 25 cases. Acta Orthop Scand 1996; 67:33-36.*
7. *MacKenzie JR, Kelley SS, Johnston RC. Total hip replacement for coxarthrosis secondary to congenital dysplasia and dislocation of the hip. Long-term results. J Bone Joint Surg Am 1996; 78:55–61.*
8. *Lai KA, Shen WJ, Huang LW, Chen MY. Cementless total hip arthroplasty and limb-length equalization in patients with unilateral Crowe type-IV hip dislocation. J Bone Joint Surg Am 2005; 87:339–345.*
9. *Shinar AA, Harris WH. Bulk structural autogenous grafts and allografts for reconstruction of the acetabulum in total hip arthroplasty. Sixteen-year-average follow-up. J Bone Joint Surg Am 1997; 79:159–168.*
10. *Gross AE, Catre MG. The use of femoral head autograft shelf reconstruction and cemented acetabular components in the dysplastic hip. Clin Orthop Relat Res 1994;298:60–66.*
11. *Kerboull M, Hamadouche M, Kerboull L. Total hip arthroplasty for Crowe type IV developmental hip dysplasia: a long-term follow-up study. J Arthroplasty 2001;16 (8 Suppl 1):170–176.*
12. *Biant LC, Bruce WJ, Assini JB, Walker PM, Walsh WR. Primary total hip arthroplasty in severe developmental dysplasia of the hip. Ten-year results using a cementless modular stem. J Arthroplasty. 2009 Jan;24(1):27-32.*

Conflict of Interest: Nil
Source of Support: None

How to Cite this Article:

Jain JK, Agarwal S, Sharma RK. Bilateral Total Hip Arthroplasty in 20 years Old Female with Neglected Developmental Dysplasia of Hip. Journal of Orthopaedic Case Reports 2014 April-June;4(2): 17-20